

# Association of Melasma in Patients with Thyroid Dysfunction and their Clinical Profile: A Cross-sectional Observational Study

NISHTHA HITENDRABHAI PATEL<sup>1</sup>, NARENDRA GANGAIAH<sup>2</sup>, VEENA THIMMAPPA<sup>3</sup>

## ABSTRACT

**Introduction:** Melasma may occur in thyroid diseases, and its manifestations may be the first presenting sign or even precede the diagnosis by many years. Melasma is difficult to treat. An initial screening of thyroid dysfunction will help in better management of both thyroid disorders and melasma.

**Aim:** To detect the proportion of thyroid dysfunction in patients with melasma and describe the clinical profile of such patients.

**Materials and Methods:** This was a cross-sectional, observational study carried out in the Department of Dermatology, Venereology and Leprosy, of a tertiary care teaching hospital of Karnataka, India from September 2020 to February 2022. Patient above or equal to 18 years of age with newly diagnosed melasma alone and no history of thyroid dysfunction were included in the study. A detailed history, using a preformed questionnaire, was taken. Wood's lamp examination, to know the depth of pigmentation,

along with thyroid dysfunction test, and antiThyroid Peroxidase (TPO) antibody was evaluated. Descriptive statistics data were analysed using a Statistical Package for the Social Sciences (SPSS) software version 20.0.

**Results:** There were 100 patients with a mean age of 35.9 years, with a predominance of female (86%) and the majority (48%) of population were housewives. The distribution of lesion was either dermal (55%) or epidermal (44%). There were 65 patients with positive antiTPO; with men (85.7%) being significantly more than women (61.6%). The distribution of pigmentations was higher for the dermal pattern (55%), among females (46) and males (9), while only one mixed pattern was seen in males.

**Conclusion:** Male melasma patients had higher positivity of antiTPO positivity than females, with significant antiTPO positivity. These patients showed more dermal pigmentations on Wood's lamp examination.

**Keywords:** antiThyroid peroxidase, Melanosis, Pigmentary disorder, Wood's lamp

## INTRODUCTION

Various clinical manifestations of different organs may be observed in a thyroid dysfunction patient, the pigmentary changes of the skin in one of them which may be observed as initial clinical features or may develop later as the disease progresses [1]. Melasma is a skin disorder associated with melanogenesis dysfunction that leads to localised, chronic acquired hypermelanosis that occurs symmetrically on sun-exposed areas of the body and affects the quality of life of an individual due to its disfiguring skin discolouration of the face [1,2].

Among the various factors involved in the aetiology of melasma are ultraviolet radiation, pregnancy, skin type, hormonal dysfunctions, and medications. Hormonal changes can be subclinical proof of an undermined hypothalamic-gonadal axis and due to increased inflammatory cytokine produced by thyroid dysfunction. The prevention of hormone regulation is observed in melasma pathogenesis [3-6].

A few studies, done on the association of melasma with thyroid disorders showed a disparity. Studies by Gopichandani K et al., Sacre RC et al., and Handel A et al., showed no differences in autoantibody levels for thyroid peroxidase, Triiodothyronine (T3), Thyroxine (T4), or Thyroid Stimulating Hormone (TSH) [7-9]. Cakmak SK et al., and Tamega Ade A et al., on the other hand, found a difference in mean serum antiTPO, T3, and TSH level that was higher in cases but not statistically significant in control [4,10] showed difference between mean serum antiTPO, T3, TSH higher in case than controls, but not statistically significant [4,10]. So, the present study was undertaken to detect the proportion of thyroid dysfunction in melasma patients and describe the clinical profile of melasma patients with thyroid dysfunction.

## MATERIALS AND METHODS

This was a cross-sectional observational study conducted from September 2020 to February 2022 at the Outpatient Department

of Dermatology Venereology and Leprosy, Sri Siddhartha Medical College and Hospital, Tumkuru, Karnataka, India. The approval of the Institutional Ethics Committee was obtained (SSMC/PG-23/IEC-5).

**Inclusion criteria:** Patient  $\geq 18$  years of age, have newly diagnosed melasma, and have no history of thyroid dysfunction.

**Exclusion criteria:** Patients on oral contraceptive pills or phenytoin; pregnant women; chronic sun exposure (daily for more than half an hour).

**Sample size calculation:** On purposive sampling, the required minimum sample size to conduct the study was 96.

$$n = \frac{z^2(1-\alpha/2) \times p(1-p)}{d^2}$$

where, Z is 1.96,

'p' is the expected proportion in population-based on previous studies, which is 50% [4].

'd' is allowable error, which allows 10% Substituting the values in the above formula,

$$n = \frac{(1.96 \times 1.96) \times 0.50(1-0.50)}{(0.1 \times 0.1)} = 96$$

## Study Procedure

Using a preformed questionnaire, a detailed history was obtained about the demographic data, duration of melasma, and clinical patterns of melasma (chin, lips, upper lip, nose, and forehead involved in the centrofacial pattern). The malar pattern and the mandibular pattern (which include cheeks, nose, and mandible ramus, respectively) were recorded. A Wood's lamp examination was performed on all the participants to determine the depth of the pigmentation, and melasma was classified as epidermal type, if there was accentuation of light, as dermal type, if there was no accentuation of light, and as mixed type when there

was a patchy enhancement of light [2]. Blood examinations for thyroid dysfunction (T3, T4, TSH, and antiTPO antibody) were performed.

## STATISTICAL ANALYSIS

Descriptive statistics data were analysed using SPSS software version 20.0. To compare thyroid function parameters between genders and clinical patterns, an Independent sample t-test was applied. The statistical significance level was set at  $p$ -value<0.05.

## RESULTS

There were a total of 100 patients included in the study. The mean age was 35.9 years, and the male-female ratio of 1:6.14 and the mean duration of lesions were  $3.23 \pm 2.26$  years [Table/Fig-1]. The majority were housewives (48), followed by teachers (28) [Table/Fig-2]. Overall, 55% had the malar type of distribution. On Wood's light examination, pigmentation was seen in either the dermal (55%) or epidermis (44%) [Table/Fig-3].

Features	Observations
Mean age	35.9 years
Gender (male/female)	14/86
Mean duration of disease	3.23 years

[Table/Fig-1]: Demographic details.

Occupation	Frequency (n)
Housewife	48
Teacher	28
Student	14
Tailor	5
Farmer	2
Clerk	1
Nurse	1
Vegetable seller	1
Total	100

[Table/Fig-2]: Occupational distribution of the patients.

Gender	Depth of Lesion			Total
	Epidermal	Dermal	Mixed	
Male	4	9	1	14
Female	40	46	-	86
Total	44	55	1	100

[Table/Fig-3]: Depth of lesion on wood's lamp examination.

Females had the most common pattern of lesion distribution (51), while males had a centrofacial pattern distribution; only one male patient had a mandibular pattern [Table/Fig-4]. On comparison of thyroid function between genders, 65 melasma patients showed positive antiTPO, with more antiTPO positive men (85.7%) as compared to women (61.6%) [Table/Fig-5].

Gender	Distribution of lesion			Total
	Centrofacial pattern	Malar pattern	Mandibular pattern	
Male	9	4	1	14
Female	35	51	-	86
Total	44	55	1	100

[Table/Fig-4]: Distribution of lesional pattern.

Seven (50%) males and 17 (19.8%) females had a high TSH; only one patient had a high T3, which was a female; and none had high T3 levels. There were insignificant differences in thyroid function parameters between male and female patients [Table/Fig-6].

Gender	antiTPO antibody		Total	p-value
	Negative	Positive		
Male	2 (14.3%)	12 (85.7%)	14 (100%)	0.682
Female	33 (38.4%)	53 (61.6%)	86 (100%)	
Total	35 (35.0%)	65 (65.0%)	100 (100%)	

[Table/Fig-5]: Comparison of antiTPO antibody between genders.

Parameters	Gender	Low	Normal	High	Mean	Std. Deviation	p-value
T3	Male (14)	0	14 (100.0%)	0	105.14	20.46	0.281
	Female (86)	1 (1.2%)	85 (98.8%)	0	113.97	29.23	
	Total	1 (1.0%)	99 (99.0%)	0	112.73	28.25	
T4	Male (14)	1 (7.1%)	13 (92.9%)	0	7.77	1.86	0.895
	Female (86)	8 (9.3%)	77 (89.5%)	1 (1.2%)	7.85	2.31	
	Total	9 (9.0%)	90 (90.0%)	1 (1.0%)	7.84	2.24	
TSH	Male (14)	0	7 (50.0%)	7 (50.0%)	11.56	15.06	0.403
	Female (86)	2 (2.3%)	67 (77.9%)	17 (19.8%)	7.18	18.54	
	Total	2 (2.0%)	74 (74.0%)	24 (24.0%)	7.79	18.09	

[Table/Fig-6]: Comparison of thyroid function between genders.

Normal range: T3-80-220 ng/dl, T4-4.5-11 mcg/dl, TSH-0.3-4.5 mIU/L.

On comparison between thyroid function and the distribution of the lesion, there was no association [Table/Fig-7,8]. On comparison between thyroid function and age group, there was no significant difference in any of the thyroid function parameters between any age groups [Table/Fig-9].

Parameters	Distribution of the lesion	Mean±Std. Deviation	t- value	p-value
T3	Centrofacial (44)	106.36±27.57	-1.959	0.053
	Malar (55)	117.42±28.15		
	Total	112.73±28.25		
T4	Centrofacial (44)	7.56±2.26	-1.085	0.280
	Malar (55)	8.05±2.25		
	Total	7.84±2.24		
TSH	Centrofacial (44)	7.60±9.99	-0.124	0.901
	Malar (55)	8.05±22.79		
	Total	7.79±18.09		
antiTPO	Centrofacial	85.10±176.31	0.652	0.516
	Malar	62.47±167.74		
	Total	71.92±170.33		

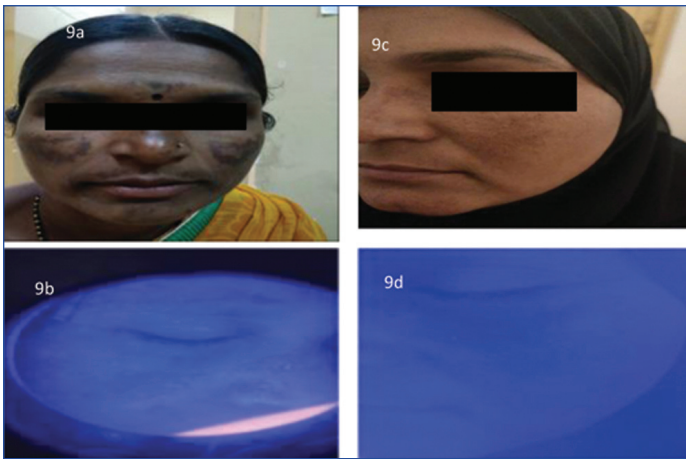
[Table/Fig-7]: Comparison between thyroid function and distribution of the lesion.

\*Centrofacial pattern involves the forehead, cheeks, upper lip, nose, and chin, malar pattern involves the cheeks and nose, There was only one case in the mandibular group, so it was excluded from the analysis.

## DISCUSSION

The interaction of hypothalamic-pituitary-thyroid axis and a strong immunoreactivity of  $\alpha$ -MSH is one of most important factor melasma pathogenesis. Thyroid dysfunction leads to increased adrenocorticotrophic hormones as a compensating mechanism, the accelerated cortisol degradation, in turn act on the melanocortin receptors in the melanocytes and induces abnormal melanogenesis [1,9-12].

Kheradmand M et al., systemic review and meta-analysis concluded that thyroid hormones and thyroid autoimmunity may also play a



**[Table/Fig-8]:** Showing centrofacial patterns: a,b) Centrofacial pattern of melasma with contrast enhancement on Wood's lamp examination indicating epidermal melasma and malar; c,d) Malar pattern of melasma showing no contrast enhancement on Wood's lamp examination indicating dermal melasma.

Parameters	Age group (in years)	N	Mean±Std. Deviation	F-value	p-value
T3	20-30	28	117.11±31.11	0.889	0.450
	31-40	41	114.78±27.08		
	41-50	25	106.68±28.06		
	51-60	6	103.50±22.30		
	Total	100	112.73±28.25		
T4	20-30	28	7.94±2.84	1.135	0.339
	31-40	41	8.14±1.78		
	41-50	25	7.14±2.23		
	51-60	6	8.20±1.77		
	Total	100	7.84±2.24		
TSH	20-30	28	13.04±31.60	1.316	0.274
	31-40	41	4.93±6.94		
	41-50	25	7.87±9.55		
	51-60	6	2.44±2.12		
	Total	100	7.79±18.09		
antiTPO	20-30	28	66.32±199.84	0.056	0.982
	31-40	41	75.96±129.67		
	41-50	25	76.82±211.17		
	51-60	6	49.98±96.21		
	Total	100	71.92±170.33		

**[Table/Fig-9]:** Relation between thyroid function and age group.

role in the pathogenesis of melasma and require further studies for confirmation [13]. Clinical data from the present study shows that serum levels of TSH, antiTPO, and antithyroglobulin antibodies were significantly higher in patients with melasma, than in those without melasma. Moreover, these differences were more severe among women with melasma [13]. Tamega Ade A et al., discovered that 25.3% of melasma patients had high TSH levels, which were lined to sever melasma caused by sun exposure [10].

On the contrary, in the present study, there was no statistically significant difference in the T3, T4, and TSH, antiTPO levels between women and men or between different age groups. There was no relationship between thyroid function and the distribution of the lesion or the depth of the lesion. Similarly, in a study by Sacre RC et al., in 20 patients with idiopathic melasma, thyrotrophic, prolactinic, and gonadotropin reserves were normal, and ovarian and thyroid function were within the normal range. It was not possible to establish an aetiological association between melasma and the observed hormone levels [8]. Yazdanfar A and Hashemi B evaluated the relationship between thyroid autoimmunity and melasma in a small Iranian study conducted in 2010 among 45 melasma-affected

females and 45 age-matched controls, which showed a statistically significant difference in the higher level of serum antiTPO levels in the patients (24.4%) as compared to the controls (6.7%), while no difference was seen in levels of antiTPO, T3, and TSH [14].

In an Indian study, statistically substantial discrepancies were found between free-testosterone means, total testosterone, LH, progesterone, estradiol, and free thyroxine of in cases and controls, in patients with melasma relative to controls, indicating the association between melasma and thyroid disorders. No association was found, however, between the magnitude of melasma and the mean levels of hormones [7]. Çakmak SK et al., melasma patient study for aetiopathogenetic factors thyroid functions and thyroid autoimmunity, and observed in melasma patients, 17.8% positive family with significant higher levels of Free T4 (FT4), TSH, and Anti-thyroglobulin (AbTg), in melasma patient and 26.7% had history of pregnancy, 17.8% used oral contraceptive and 13.3% intense sunlight exposure in melisma [4].

Furthermore, there are reports of more hyperthyroidism patient with melasma and autoimmune thyroid dysfunction due increased levels of inflammatory cytokines that act on epidermal melanin unit to induce pigmentation production [15,16]. In the present study, we observed that 65 melasma patients had positive antiTPO, with more antiTPO positive men (85.7%) as compared to women (61.6%). While Kiani A et al., studied on 45 melasma patient, they noted 37.8% had thyroid dysfunction compared to 11.1% of controls and concluded that, thyroid disorder especially autoimmune thyroid disorder is significantly higher in melasma patients with thyroid disorder [17]. In the study by Rostami Mogaddam M et al., study on nonpregnant melasma women with thyroid dysfunction and autoimmunity, 70 cases were age-matched healthy females with no history of melasma. Statistically significant higher levels of patients with melasma had 18.5% thyroid disorders, and 15.7% were positive for antiTPO, compared to only 4.3% in control subjects [18]. Melasma is triggered by various factors, including pregnancy, oral contraceptive use, sunlight, and genetic factors. Autoimmunity of the thyroid and thyroid hormones can also play a role in melasma pathogenesis, and further studies are needed for confirmation.

### Limitation(s)

The study was observational, and the number of patients enrolled in the present prospective single centre study represents a relatively small sample size. The study was carried out in a hospital, which is situated in an urban area. So, the result of the present study cannot be generalised. Follow-up is needed to study the prognosis of melasma and thyroid disorders.

### CONCLUSION(S)

Melasma is a multifactorial disorder with many possible underlying causes. Melasma can be one of the cutaneous manifestations of undiagnosed thyroid dysfunction. In the present study, there was clinical evidence of a relationship between melasma and thyroid dysfunctions, but it was not statistically significant. Therefore, efforts should be made, to identify the primary cause of melasma for proper management.

### REFERENCES

- [1] Kasumagic-Halilovic E. Thyroid disease and the skin. *Annals Thyroid Res.* 2014;1(2):27-31.
- [2] Sarkar R, Gokhale N, Godse K, Ailawadi P, Arya L, Sarma N, et al. Medical management of melasma: A review with consensus recommendations by Indian pigmentary expert group. *Indian J Dermatol.* 2017;62:558-77.
- [3] Muller I, Rees DA. Melasma and endocrine disorders. *Pigmentary disorders.* 2014;S1:001. Doi: 10.4172/2376-0427.S1-001.
- [4] Çakmak SK, Özcan N, Kılıç A, Koparal S, Artüz F, Çakmak A, et al. Etiopathogenetic factors, thyroid functions and thyroid autoimmunity in melasma patients. *Postepy Dermatol Alergol.* 2015;32(5):327-30.
- [5] Aishwarya K, Bhagwat PV, John N. Current concepts in melasma- A review article. *J Skin Sex Transm Dis.* 2020;2(1):13-17.

- [6] Handel AC, Miot LD, Miot HA. Melasma: a clinical and epidemiological review. *An Bras Dermatol*. 2014;89(5):771-82.
- [7] Gopichandani K, Arora P, Garga U, Bhardwaj M, Sharma N, Gautam R. Hormonal profile of melasma in Indian females. *Pigment International*. 2015;2(2):85-90.
- [8] Sacre RC, Fernandes NC, Vaisman M, Tendrich M. Melasma idiopático: avaliação das funções tireoidiana, prolactínica e gonodalfeminina. *An Bras Dermatol*. 1996;71:195-98.
- [9] Handel A, Lima P, Tonolli V, Miot L, Miot HA. Risk factors for facial melasma in women: a case-control study. *British Journal of Dermatology*. 2014;171(3):588-94.
- [10] Tamega Ade A, Miot LD, Bonfietti C, Gige TC, Marques ME, Miot HA. Clinical patterns and epidemiological characteristics of facial melasma in Brazilian women. *J Eur Acad Dermatol Venereol*. 2013;27(2):151-56.
- [11] Martin NM, Smith KL, Bloom SR, Small CJ. Interactions between the melanocortin system and the hypothalamo-pituitary-thyroid axis. *Peptides*. 2006;27(2):333-39.
- [12] Miot L, Miot HA, Silva Md, Marques M. Physiopathology of melasma. *Anais brasileiros de dermatologia*. 2009;84(6):623-35.
- [13] Kheradmand M, Afshari M, Damiani G, Abediankenari S, Moosazadeh M. Melasma and thyroid disorders: a systematic review and meta-analysis. *International Journal of Dermatology*. 2019;58(11):1231-38.
- [14] Yazdanfar A, Hashemi B. Association of melasma with thyroid autoimmunity: a case-control study. *Iranian Journal of Dermatology*. 2010;13(20):02-04.
- [15] Miot LD, Miot HA, Silva MG, Marques ME. Physiopathology of melasma. *Anras Dermatol*. 2009;84(6):623-35.
- [16] Rozing MP, Westendorp RG, Maier AB, Wijsman CA, Frolich M, deCraen AJ, et al. Serum triiodothyronine levels and inflammatory cytokine production capacity. *Age (Dordr)*. 2012;34(1):195-201.
- [17] Kiani A, Ahmari M, Rezvan FMR. Association of melasma with thyroid disorders: A case-control study. *Iranian Journal of Dermatology*. 2006;9:154-58.
- [18] Rostami Mogaddam M, IranparvarAlamdari M, Maleki N, SafaviArdabili N, Abedkouhi S. Evaluation of autoimmune thyroid disease in melasma. *Journal of Cosmetic Dermatology*. 2015;14(2):167-71.

**PARTICULARS OF CONTRIBUTORS:**

1. Junior Resident, Department of Dermatology, Sri Siddhartha Medical College, Tumkuru, Karnataka, India.
2. Professor, Department of Dermatology, Sri Siddhartha Medical College, Tumkuru, Karnataka, India.
3. Associate Professor, Department of Dermatology, Sri Siddhartha Medical College, Tumkuru, Karnataka, India.

**NAME, ADDRESS, E-MAIL ID OF THE CORRESPONDING AUTHOR:**

Dr. Veena Thimmappa,  
Associate Professor, Department of Dermatology, OPD Block Sri Siddhartha  
Medical College, Tumkuru, Karnataka, India.  
E-mail: veenathimmappa@gmail.com

**PLAGIARISM CHECKING METHODS:** [Jain H et al.]

- Plagiarism X-checker: Jun 23, 2022
- Manual Googling: Nov 15, 2022
- iThenticate Software: Dec 17, 2022 (9%)

**ETYMOLOGY:** Author Origin**AUTHOR DECLARATION:**

- Financial or Other Competing Interests: None
- Was Ethics Committee Approval obtained for this study? Yes
- Was informed consent obtained from the subjects involved in the study? Yes
- For any images presented appropriate consent has been obtained from the subjects. NA

Date of Submission: **Jun 16, 2022**Date of Peer Review: **Jul 28, 2022**Date of Acceptance: **Dec 24, 2022**Date of Publishing: **Apr 01, 2023**