



Positions for percutaneous nephrolithotomy: Thirty-five years of evolution

Theocharis Karaolides, Konstantinos Moraitis, Christian Bach, Junaid Masood & Noor Buchholz

To cite this article: Theocharis Karaolides, Konstantinos Moraitis, Christian Bach, Junaid Masood & Noor Buchholz (2012) Positions for percutaneous nephrolithotomy: Thirty-five years of evolution, Arab Journal of Urology, 10:3, 307-316, DOI: [10.1016/j.aju.2012.06.005](https://doi.org/10.1016/j.aju.2012.06.005)

To link to this article: <https://doi.org/10.1016/j.aju.2012.06.005>



© 2012 Arab Association of Urology



Published online: 05 Apr 2019.



Submit your article to this journal [↗](#)



Article views: 1341



View related articles [↗](#)




Citing articles: 1 View citing articles [↗](#)



Arab Journal of Urology
(Official Journal of the Arab Association of Urology)

www.sciencedirect.com



REVIEW

Positions for percutaneous nephrolithotomy: Thirty-five years of evolution

Theocharis Karaolides ^a, Konstantinos Moraitis ^{a,b}, Christian Bach ^a,
Junaid Masood ^a, Noor Buchholz ^{a,*}

^a Endourology and Stone Services, Barts Health NHS Trust, London, UK

^b The Corfu Center of Endourology & Stone Services, Greece

Received 24 May 2012, Received in revised form 9 June 2012, Accepted 12 June 2012

Available online 11 August 2012

KEYWORDS

Percutaneous nephrolithotomy;
PCNL;
Positions;
Prone;
Supine;
Lateral;
Flank;
Endoscopic intrarenal surgery

ABBREVIATION

PCNL, percutaneous nephrolithotomy

Abstract Objectives: To present the chronological development of the different positions described for percutaneous nephrolithotomy (PCNL), in an attempt to identify the reasons for their development and to highlight their specific advantages and disadvantages.

Methods: Previous reports were identified by a non-systematic search of Medline and Scopus.

Results: The classic prone position for PCNL was first described in 1976. The technique was gradually standardised and PCNL with the patient prone became the generally accepted standard approach. In the next 35 years many other positions were described, with the patient placed prone, lateral or supine in various modifications. Modifications of the classic prone position in the early 1990s aimed to provide the option of a simultaneous retrograde approach during the procedure. As PCNL became more popular the lateral position was first described in 1994, to allow the application of PCNL to patients who were unable to tolerate being prone because of their body habitus. The supine position for percutaneous access was originally described even before 1990, but become more popular after 2007 when the Galdakao

* Corresponding author. Address: Department of Urology, Barts Health NHS Trust, London E1 1BB, UK.

E-mail address: noor.buchholz@bartshealth.nhs.uk (N. Buchholz).

Peer review under responsibility of Arab Association of Urology.



Production and hosting by Elsevier

modification was reported. Several other modifications of the supine position have been described, with the latest being the flank-free modified supine position, which allows the best exposure of the flank among the supine positions. Each position has its specific advantages and disadvantages.

Conclusion: Urologists who perform PCNL should be familiar with the differences in the positions and be able to use the method appropriate to each case.

© 2012 Arab Association of Urology. Production and hosting by Elsevier B.V. All rights reserved.

Introduction

Percutaneous nephrolithotomy (PCNL) is used widely and has almost completely replaced open surgery for the removal of large and complex renal calculi. Since its first description by Fernstrom and Johansson [1], PCNL has traditionally been done with the patient prone, combining a high success rate and acceptable morbidity.

As PCNL was used more frequently it became evident that the prone position was not optimal for all patients, particularly the morbidly obese or those with respiratory compromise. This insight, and the demand for easier and more comfortable access to the entire urinary tract to combine retrograde and antegrade endoscopic surgery, led to the introduction of alternative patient positions for PCNL.

Some of these were not widely accepted in the urological community but all of them had a significant role in the dynamic process of further refinement. The purpose of the present review is to present the chronological development of the different positions (Table 1) [1–11] that have been described for PCNL, to investigate the reasons for their development, and to highlight their specific advantages and disadvantages (Table 2).

Evidence acquisition

Using a non-systematic search of Medline and Scopus from 1976 to 2011, previous relevant reports were

identified using the keywords ‘percutaneous nephrolithotomy’, ‘PCNL’, ‘position’, ‘supine’ and ‘prone’. Further reports were acquired from the references of the retrieved articles, and standard textbooks were consulted. Only papers written in English were included.

Evidence synthesis: positions for PCNL

Prone

The classic prone position (Fig. 1). When PCNL was initially described in 1976 the prone position was chosen because it was believed that this would be the safest way to avoid damage to the colon and visceral organs. The technique was standardised over the following years as a two-stage procedure. The first part is with the patient supine, to give anaesthesia and gain retrograde access to the upper urinary tract. Then the patient is repositioned prone for the main part of the procedure. Rolled supports are placed under the thorax and the upper abdomen or on both sides, extending from shoulder to hip, to facilitate ventilation [12]. Padding is placed under all pressure points (knees, feet, forehead, eyes, elbows, fingers) and the shoulders, and the elbows are carefully positioned to prevent brachial plexus injury [13]. The percutaneous tract to the kidney is established under fluoroscopy or ultrasonographic guidance, and the stone is removed.

Table 1 A timeline of positions for PCNL.

Year	Ref	Position	Type	Comment
1976	[1]	Classic prone	Prone	First description of percutaneous stone extraction
1988	[8]	Reverse lithotomy	Prone	First simultaneous antegrade and retrograde access
1990	[9]	Original supine	Supine	First series of PCNL while supine. Initial case reports 2 years before
1990	[9]	Modified supine for simultaneous PCNL and ureteroscopy	Supine	
1991	[2]	Split-leg prone	Prone	
1993	[3]	Flank roll position	Supine	For patients having preoperative percutaneous access
1994	[4]	Lateral decubitus	Flank	First PCNL in the lateral position
2007	[10]	Galdakao-modified Valdivia	Supine	Renewed the interest for supine position
2007	[5]	Crossed-leg supine	Supine	
2008	[7]	Barts technique	Flank	Very good simultaneous ante- and retrograde access
2008	[11]	Complete supine	Supine	No support is placed under the flank
2009	[6]	Prone-flexed	Prone	
2012	In press	Barts flank-free modified	Supine	The best exposure of the flank among the supine positions

Table 2 Advantages and disadvantages of positions for PCNL.		
Position	Advantages	Disadvantages
<i>Prone</i>		
Classic prone	Excellent exposure of lumbar area	Patient repositioning during the procedure
Classic prone with supporting equipment	Easier access to upper pole Kidney close to puncture site and less mobile	Hard to manage cardio-respiratory emergencies Respiratory/cardiovascular function compromised
Reverse lithotomy	Depended renal pelvis and thus increased pressure (better visibility and room for movement)	Increased risk of injuries from pressure (less if special mattress is used) (less if supporting equipment is used)
Split leg prone		Theoretical risk of ocular complications
Prone-flexed		Surgeon standing/non-ergonomic position Theoretically greater exposure to radiation Retrograde access not possible in classic prone (feasible in 'split leg' and 'reverse lithotomy')
<i>Lateral</i>		
Lateral decubitus and lateral flexed	Can be used in patients with severe obesity, kyphoscoliosis	Patient repositioning is required (easier than in prone position)
'Barts technique'	Less impact on respiratory/cardiac function Good exposure of flank Option for simultaneous retrograde access General anaesthesia can be avoided	Difficult access to kidney with fluoroscopy
<i>Supine</i>		
Original Valdivia	Patient is positioned and draped once	Reduced exposure of flank area (less in the 'Barts flank-free' position)
Modified Valdivia	Comfortable position for patient	Access to posterior calyces not always possible
Flank roll	Surgeon in ergonomic position	Kidney sometimes more mobile (difficult puncture)
Crossed leg	Theoretically less exposure to radiation	Instrument movements can be restricted. (less in the 'Barts flank-free' position)
Galdakao	Excellent control of airway by anaesthetists	Collapsed collecting system because of reduced pressure makes nephroscopy more demanding
Complete supine	Allows easier retrograde access	
Barts flank-free	Dependent access (spontaneous evacuation of fragments, less fluid absorption) General anaesthesia can be avoided	

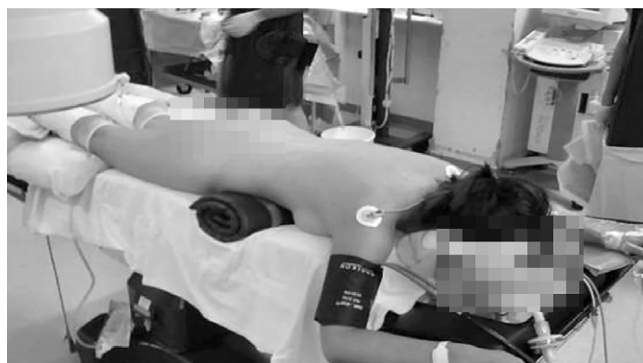

Figure 1 The prone position.

The main advantage of the prone position is that it exposes completely the lumbar area. This gives the surgeon ample room to place the puncture, allows several accesses/tracts, and provides enough space for manipulation with the instruments. Upper-pole puncture is facilitated in the prone position because of the posteromedial location of the upper pole, which is closer to

the posterior abdominal wall [6]. However, PCNL with the patient prone has several disadvantages. First, the patient must be repositioned after the first stage. This increases the operating time, and could cause injury to the patient and jeopardise the airway access. It is very difficult or almost impossible for the anaesthetist to manage an eventual cardio-respiratory emergency. Lying on the abdomen creates further anaesthesiological difficulties by reducing lung compliance as a result of the abdominal compression, and by reducing cardiac output [7]. The patient is bedded uncomfortably with the risk of creating pressure lesions. The prone position is generally associated with an increased rate of ophthalmological complications, as seen mostly from spinal operations. Direct compression might cause injury to the orbit and corneal abrasions. Also, intraocular pressure is raised during the operation and is suspected to lead to the rare complication of postoperative visual loss due to ischaemic oculopathy [14,15]. For patients with ankylosing spondylitis or other spinal or lower limb deformities, the prone position might not be possible. Finally, there is a theoretically greater risk

of radiation exposure for the surgeon when the patient is supine, because the surgeon stands close to the patient, working with the instruments in perpendicular direction [6].

Better patient positioning in the classic prone position (Fig. 2)

Various supporting equipments have been developed to minimise the risk of pressure injury, reduce the risk of position-related complications, and improve the ventilation and circulation of the patient. For example, the rolled supports can be replaced by the Cloward surgical saddle (Cloward Instruments Corp., Honolulu, Hawaii) [12] or the Montreal mattress (Teasdale Hospital Equipment, Manchester, UK) [16], embedding the patient in a more comfortable, slightly flexed posture with less pressure on the abdomen. To better position the head, the Proneview protective helmet system (Dupaco, Ocean-side, CA, USA) was developed, which protects the critical cephalic pressure points and the airways [7].

The reverse lithotomy position

To allow simultaneous retrograde access to the upper urinary tract during PCNL, a modification of the classic prone position became necessary. In 1988, Lehman and Bagley [8] reported successful results with this combined approach in three female patients. According to the initial description, the patient is placed prone with the legs abducted at the hips, and the thighs and knees fixed in plastic cradles specifically modified for this purpose. The caudal end of the operating table is lowered as far as possible. The operator approaching from the caudal end of the table has access to the urethra, bladder and ureter with flexible instruments.

The split-leg prone position (Fig. 3)

The same group of authors who described the reverse lithotomy position 3 years later reported the split-leg prone position that allowed easier simultaneous percutaneous and transurethral access both in female and male

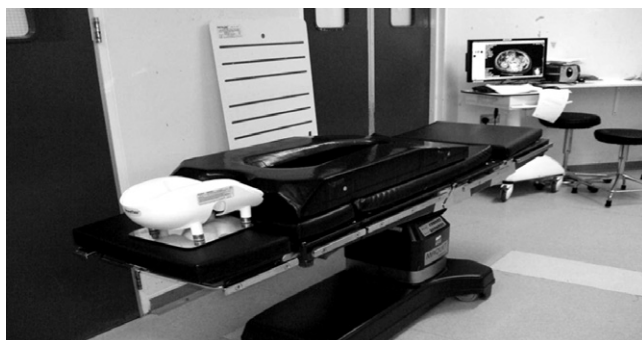

Figure 2 The Montreal mattress, with the Proneview helmet.

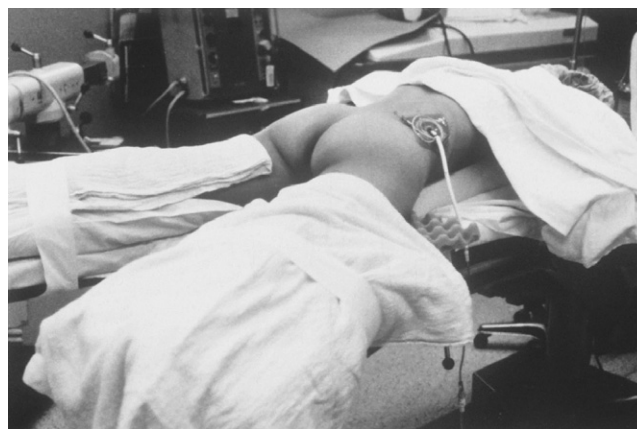


Figure 3 The split-leg position. (Taken from [3] with permission from the author, courtesy of Professor Michael Grasso).

patients [2]. The patient is anaesthetised while supine and then turned prone on a standard endourological table with split-leg adapters. The patient's legs are appropriately padded, secured independently and solely abducted at the hips without being flexed. The genitalia are positioned at the bottom of the operating table, making room for retrograde access. The flank and the genital area are separately prepared and draped. Using flexible instruments, the bladder and upper urinary tract are accessed, although this can be challenging. The authors report that many endourological procedures, including intracorporeal lithotripsy, can be performed in this position [2,3].

The prone-flexed position (Fig. 4)

Recently a modification of the prone position was described which incorporates a flexed position of the patient during the procedure [6]. After the patient is turned to prone the table is flexed 30–40° to open the space between the 12th rib and the posterior iliac crest. This flexion prevents the exaggeration of the anterior lordosis that occurs in the classic prone position. More

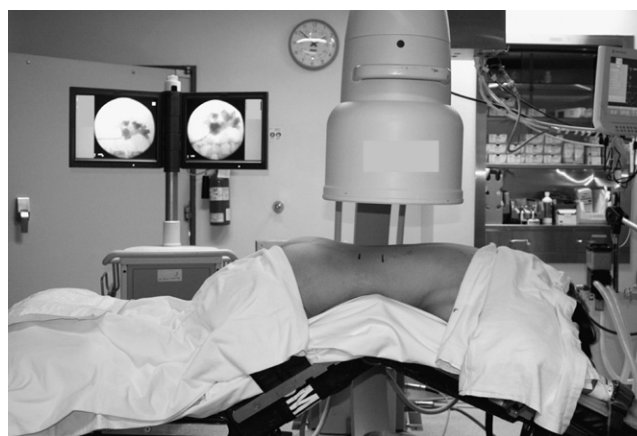

Figure 4 The prone-flexed position. (Taken from [6] with permission from the author, courtesy of Dr. R. John D'A. Honey).

working space is created, potential interference from the buttock with the nephroscope during rigid nephroscopy through the lower pole is minimised, and the kidneys are displaced inferiorly in the retroperitoneum. As a result the puncture can be made more caudally. However, this position impairs even more the patient's respiration and circulation. Airway pressures are increased, the cardiac index is decreased and the inferior vena cava can be transiently obstructed.

Lateral positions

The lateral decubitus and lateral flexed position

Some patients are unable to tolerate anaesthesia while prone because of their body habitus. Kerbl et al. [4] in 1994 first performed PCNL in a morbidly obese patient placed in the lateral position. Later other authors reported good results using this technique in obese, kyphotic and high-risk patients [17–19]. Urologists are familiar with this position, as it is used in open and laparoscopic renal surgery.

Initially the patient is anaesthetised while supine, when the retrograde contrast studies are conducted. The patient is then turned into the lateral position with the legs slightly bent, lying on the unaffected side and exposing the flank through which the access is made. A wedge support can be placed under the patient's torso. Both arms are supported in separate adapters and flexed slightly at the elbow. A modification of the pure lateral position, the lateral flexed position, has the additional advantage of significantly increasing the operating field. The operating table is flexed, which widens the space between the 12th rib and the iliac crest, flattening the folds of adipose tissue and facilitating percutaneous access [13].

The advantage of the lateral position is that they can be used in patients who could not tolerate being prone. Especially helpful for the morbidly obese patients is that in the lateral position the pendulous abdomen is displaced sideways, either on the operating table or on an additional support, facilitating respiration and general anaesthesia. Furthermore, as the patient is not lying prone, the procedure can be carried out safely even under regional anaesthesia, thus avoiding the risks of general anaesthesia, and allowing the patient to communicate with the anaesthetist and observe the procedure [17].

The main disadvantage in this position is the unusual fluoroscopic view of the kidney, which can also be obscured by the underlying spine. Maintaining the correct orientation and accurately puncturing the selected calyx is difficult, and can result in increased exposure to radiation of the surgical team. Using the 'bull's-eye' puncture technique might not be possible, as the metal side-rails of the table interfere with the fluoroscopic image. Alternatively, the 'triangulation' technique [13] or ultrasonographic guidance can be used, but this requires

additional expertise and equipment [17,19]. The patient must be repositioned during the procedure, although this is easier and poses fewer risks than repositioning towards the prone position.

The modified lateral position for simultaneous antegrade and retrograde access—the 'Barts technique' (Fig. 5)

This modified hybrid position was described to combine the advantages of the lateral position with the option of easier retrograde access to the upper urinary tract [20,21]. The patient is placed in the lithotomy position with the ipsilateral hemi-pelvis tilted by 45°, supported by a foam wedge. The torso is twisted to the contralateral side, with the shoulders perpendicular to the operating table. The ipsilateral lower limb is slightly flexed in a ventral direction and follows the lateral rotation of the trunk, while the contralateral lower limb remains fully abducted. In this position the flank is sufficiently exposed, providing a wide choice of puncture sites and a wide angle for handling the antegrade instruments. Percutaneous access is made close to the posterior axillary line, and the direction of the puncture needle is within the horizontal plane towards the desired calyx [21].

Simultaneous ante- and retrograde access allows the treatment of complex unilateral upper urinary tract pathology [22]. Another advantage is that repositioning of the patient is minimal, thus saving operative time and reducing the risk of injuring the patient. However, this position cannot be used for every patient as it requires musculoskeletal mobility and flexibility of the spine. Percutaneous access guided by fluoroscopy can be challenging. A similar position with the legs bent in a lower position was described recently [23].

Supine positions

The original Valdivia supine position (Fig. 6)

In 1987–88, Valdivia-Uria et al. [9] reported a safe percutaneous access to the kidney with the patient

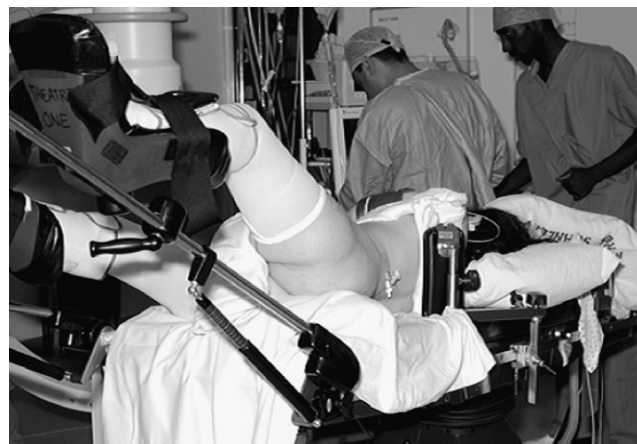

Figure 5 'The Barts technique'.

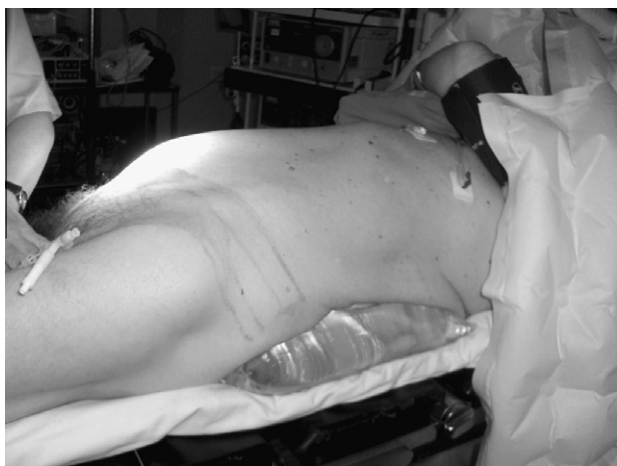

Figure 6 The ‘Valdivia’ supine position (courtesy of Professor José Gabriel Valdivia Uría).

supine and 10 years later they reported the *in vivo* experience [24]. Several other authors have also reported large series of patients treated in the same position [25–28]. As the abdominal wall is punctured more laterally, away from the lumbar muscles, movements of the endoscopic instruments are less restricted. The direction of the tract preserves a low pressure in the renal pelvis, and thereby reduces the risk of fluid absorption and allows even spontaneous clearance/washout of fragments. According to anatomical CT studies, the risk of colon perforation might even be less than in the prone position, as the bowel can float free in the uncompressed abdomen and is not pressed towards or behind the kidney [9,29,30].

The main drawback of the supine position is that the flank is not fully exposed, which makes access to the posterior-medially lying upper pole more difficult and provides less availability for multiple accesses. The operating table and the patient’s hips might also restrict instrument manipulation. The absence of abdominal compression leaves the kidney more mobile, which can make puncture and dilatation of the tract more challenging [25]. Some calyces are dependant and collect fragments during the disintegration of the stone. Finally, the low intrarenal pressure leaves the collecting system less expanded and therefore nephroscopy and manipulations can be more difficult.

The modified Valdivia position for simultaneous PCNL and ureteroscopy (Fig. 7)

This modification was described by Valdivia et al. [9] to allow simultaneous rigid ureteroscopy during PCNL. The difference from the original supine position is that the legs are flexed in supports, with the ipsilateral leg more elevated and the contralateral more descended, to facilitate the use of a rigid ureteroscope. Valdivia [13] prefers the classic supine position if a flexible

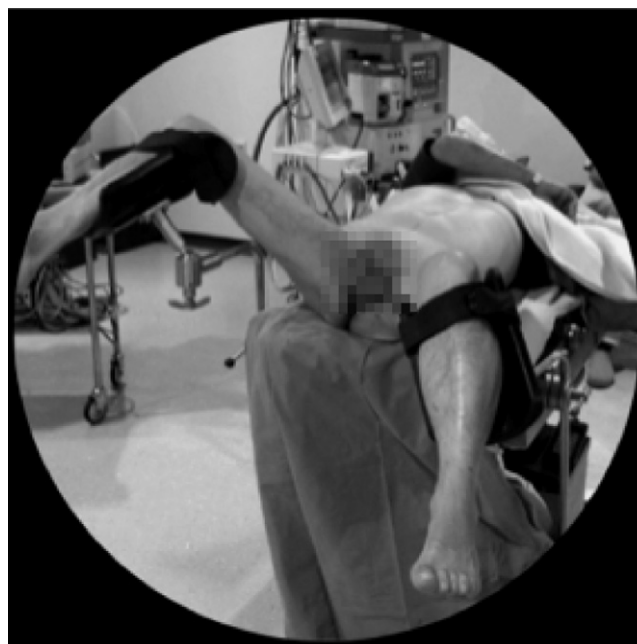

Figure 7 The modified ‘Valdivia’ position (courtesy of Professor José Gabriel Valdivia Uría).

ureteroscope is to be used, and proposes this modification only for rigid ureteroscope.

The modified flank roll position

At present, many departments perform percutaneous surgery after the kidney has been punctured under local anaesthesia and sedation in the radiology department. During the first years of PCNL this was the routine [31]. In 1993 Grasso et al. [3] described the modified flank roll position for patients who already had a nephrostomy *in situ*. These authors suggested that this position is suitable when the preoperative assessment showed that the procedure might be completed retrogradely, and a percutaneous tract would only be a complementary access for flexible instruments if needed. The patient is placed in the standard dorsal lithotomy position, having the flank with the percutaneous nephrostomy tilted by 45° and padded to allow access to the nephrostomy tube. The upper extremity lies across the thorax. Both the nephrostomy site and the genitalia are prepared and draped. The limited exposure of the flank might not allow a primary puncture and manipulations with rigid nephroscopes.

The crossed-leg supine position

This variation of the original Valdivia position was described in 2007 and consists of crossing the ipsilateral leg over the contralateral [5]. A 30° inclination of the torso is achieved by placing a cushion below the ipsilateral flank. The arms are placed similarly to those in the original Valdivia position.

According to these authors, crossing the legs increases the distance from the lower rib to the iliac crest, and facilitates calyceal puncture and nephrostomy tract dilatation. Also, the skin and muscles of the flank are stretched, which further helps to establish percutaneous access. The authors also suggested that this variation enables a more comfortable position for the assistant next to the surgeon.

The Galdakao-modified Valdivia position (Fig. 8)

This position was described by Ibarluzea et al. [10] in 2007 and renewed the attention of the urological community on supine PCNL. Other authors confirmed that the operation in this position is a safe, practical and versatile procedure, with high success rates and has important advantages over the prone position [32–34].

The main characteristic is a slight lateralisation of the Valdivia supine position, with the contralateral leg flexed. The patient is placed in an intermediate supine-lateral position with a 3-L bag placed to raise the flank. The ipsilateral leg is extended and the contralateral leg is abducted and flexed, achieving a modified lithotomy position.

The Galdakao-modified Valdivia position combines the surgical and anaesthesiological advantages of the original Valdivia position with the advantage of simultaneous retrograde access to the kidney. The patient needs to be draped only once and repositioning is not necessary. There is more space for manipulating the instruments than in the original supine position. The drawbacks of this modification do not differ from those known for the original supine position [28].

The complete supine position (Fig. 9) [35]

PCNL in a complete supine position with no flank support was described by Falahatkar et al. [11] who reported this technique to be safe and feasible in all patients [36]. The patient is placed supine at the edge of the table, with the legs extended and the arms stretched and abducted in supports.

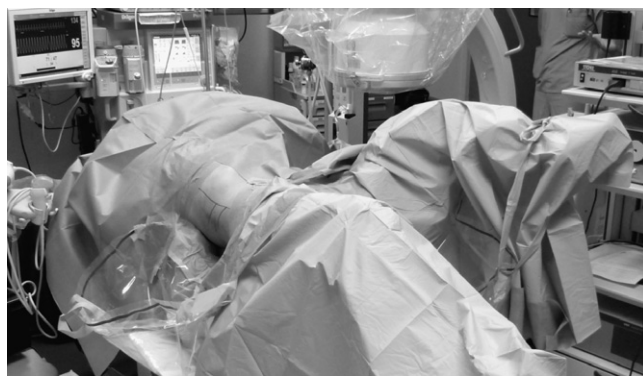

Figure 8 The Galdakao-modified Valdivia position (courtesy of Dr. Cesare Marco Scoffone).

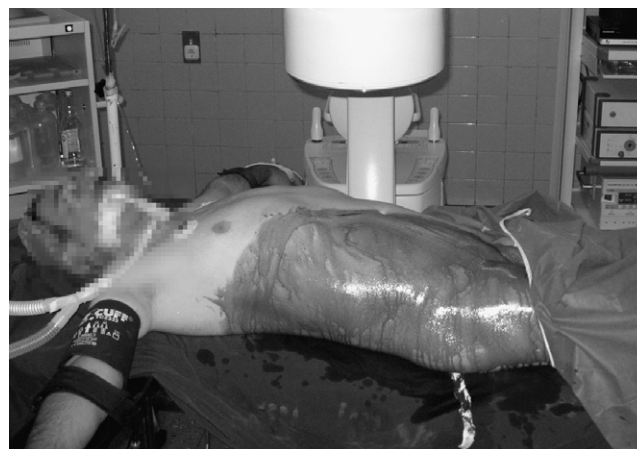


Figure 9 The complete supine position. (Taken from [35] with permission from the author, courtesy of Dr. Siavash Falahatkar, Professor of Urology).

The advantages are similar to those of other supine positions. Also, the absence of flank support prevents the cephalad sliding of the kidney, making upper-pole puncture more feasible. To further facilitate this the authors proposed using lung inflation to lower the kidneys [37]. Finally, the fluoroscopic view of the kidney is not overlapped by the vertebrae, as can occur in semi-supine positions [11].

The flank-free supine position

In 2007 Cormio et al. [38] described a novel position for placing a nephrostomy. The patient is put in a more oblique position with two towels under the shoulder and hip, leaving the flank exposed. The ipsilateral arm is placed over the chest and the contralateral arm is abducted. The authors did not describe percutaneous surgery in this position but they showed the benefit of better exposure of the flank by removing the supporting saline bag from the loin.

The Barts flank-free modified supine position (Fig. 10)

For the last 2 years we have been using this new modification of the supine position that better exposes the flank, as described above, but also incorporates a lithotomy position, and is termed the 'Barts flank-free modified supine position' [39,40]. The patient is supine with a 15° tilt of the ipsilateral flank made by using a saline bag under the rib cage and a gel pad under the pelvis. The ipsilateral arm lies across the chest. The legs are placed in the lithotomy position with the ipsilateral leg relatively extended and the contralateral leg abducted and slightly elevated.

The main advantage is that it exposes the flank better than with all other supine positions for PCNL, giving optimal space for renal access and manipulation, as no support is placed immediately under the working area.

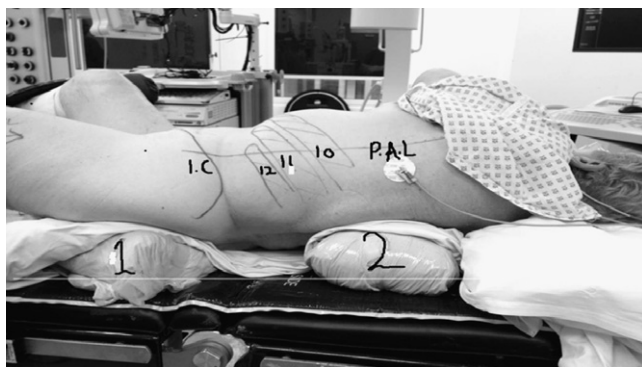

Figure 10 The Barts flank-free supine position.

The patient is comfortable with no stress in the spine, as the torso is minimally rotated. A fluoroscopic view of the kidney is easily achieved with minimal rotation of the C-arm, while better radiological safety is ensured as the surgeon's hands are less exposed. The kidney lies in a neutral position and is less mobile, enabling an easier access and dilatation of the tract. Ideal conditions for simultaneous antegrade and retrograde access are offered. The nephrostomy tract is almost horizontal, which enables a better washout of fragments and a lower intrarenal pressure.

Comment

Although, the prone position is traditionally considered the classic format for PCNL, over the years and as PCNL became more widespread the limitations of this approach were recognised. Anaesthetic concerns, especially in the morbidly obese or other high-risk patients, and the need to reposition the patient during the procedure, were the reasons that initially provoked urologists to explore alternative positions. At the same time the significant improvements in flexible ureteroscopy [41] and intracorporeal lithotripsy [42] increased the efficacy of retrograde intrarenal surgery. As a result there was increased interest in combining simultaneous antegrade and retrograde endoscopic access to the urinary tract, and this was another reason for exploring new positions for PCNL.

In an effort to address some of the drawbacks of having patients placed on their abdomen and padded only by rolled supports, various equipment was introduced that made this position more comfortable, improved ventilation and circulation, and reduced the risk of pressure injury [7,12,13]. An additional benefit of these devices is that the hips of the patient are slightly flexed, increasing the working space on the flank.

To achieve better flank exposure the prone-flexed position was described, using the flex option of the operating table. Here the working space is increased even further as the ribs are rotated cephalad and at the same time the kidneys move caudally, allowing the puncture to be made lower on the torso, thereby reducing the risk

of pleural complications. It was estimated that 45% fewer supra-11th rib punctures would be necessary to access the most superior calyx [6].

With the increasing incidence of obese patients and the evidence that stone disease is linked to the metabolic syndrome [43], it was important that solutions for PCNL in this group of patients were developed. Morbidly obese patients have a constantly elevated intra-abdominal pressure which restricts the respiratory reservoir. This is aggravated under general anaesthesia with muscle paralysis and is further worsened if the patient is placed prone. Haemodynamic compromise also occurs when prone, by compression of the inferior vena cava and iliac veins, leading to a decrease in venous return and in cardiac pre-load [17]. To overcome these problems the lateral position was introduced in PCNL. The 'Barts technique' combines the advantages of the lateral position with the opportunity for complete endourological treatment in one step [21]. Lateral positions have clear benefits and indications, but are mostly used in specialised centres for selected patients, mainly because access to the kidney is technically more difficult.

Professor Valdivia-Uria described the supine position 25 years ago, and its many advantages, as described above. However, there was an astonishingly small acceptance by the urological community until Ibarlueza et al. [10] described the Galdakao-modified Valdivia supine position in 2007, which allowed comfortable simultaneous antegrade and retrograde access to the whole urinary tract, as well as the possibility of combining laparoscopy and endourology (laparo-endoscopic techniques). The 'Barts flank-free modified supine position' is a further refinement of the supine position, as it allows easier manipulation from the percutaneous access. Probably the greatest concern that prevented (or at least delayed) the wide acceptance of supine positions was the risk of colon perforation and visceral organ injury. However, the reported rate for colon perforation in the prone and supine positions is similar ($\approx 0.5\%$) [44]. Contrary to what was assumed about the anatomical position of the organs when prone, CT studies showed that the risk of colon perforation should actually be less when the patient is supine [44,45]. Both reports showed that the two positions have a similar rate of complications, similar stone-free rate and mean days of hospital stay, while supine positioning significantly decreases the operative time.

Conclusion

There has been a significant development in positions for PCNL since the first description. A multitude of variations has aimed to overcome the limitations inherent in the classical prone and initial supine positions. Urologists who perform PCNL should be familiar with the differences in the positions and be able to use the method appropriate for each patient.

Conflicts of interest

None disclosed.

Source of funding

None disclosed.

Acknowledgements

We acknowledge the following people, for their kind offer of images for this article: Mr. Junaid Masood, London, UK. Professor Michael Grasso, New York, USA. Professor Demetrius Bagley, Philadelphia, USA. Dr. R. John D'A Honey, Toronto, Canada. Professor José Gabriel Valdivia Uria, Zaragoza, Spain. Dr. Cesare Marco Scoffone, Torino, Italy. Professor Siavash Falahatkar, Rasht, Iran.

References

- [1] Fernstrom I, Johansson B. Percutaneous pyelolithotomy. A new extraction technique. *Scand J Urol Nephrol* 1976;**10**:257–9.
- [2] Nord RC-GA, Bagley DH. Prone split-leg position for simultaneous retrograde ureteroscopic and percutaneous nephroscopic procedures. *J Endourol* 1991;**5**:13–6.
- [3] Grasso M, Nord R, Bagley DH. Prone split-leg and flank roll positioning: simultaneous antegrade and retrograde access to the upper urinary tract. *J Endourol* 1993;**7**:307–10.
- [4] Kerbl K, Clayman RV, Chandhoke PS, Urban DA, De Leo BC, Carbone JM. Percutaneous stone removal with the patient in a flank position. *J Urol* 1994;**151**:686–8.
- [5] Neto EA, Mitre AI, Gomes CM, Arap MA, Srougi M. Percutaneous nephrolithotripsy with the patient in a modified supine position. *J Urol* 2007;**178**:165–8.
- [6] Ray AA, Chung DG, Honey RJ. Percutaneous nephrolithotomy in the prone and prone-flexed positions: anatomic considerations. *J Endourol* 2009;**23**:1607–14.
- [7] Papatsoris A, Masood J, El-Husseiny T, Maan Z, Saunders P, Buchholz NP. Improving patient positioning to reduce complications in prone percutaneous nephrolithotomy. *J Endourol* 2009;**23**:831–2.
- [8] Lehman T, Bagley DH. Reverse lithotomy. Modified prone position for simultaneous nephroscopic and ureteroscopic procedures in women. *Urology* 1988;**32**:529–31.
- [9] Valdivia JG, Valer J, Villarroya S, Lopez J, Bayo A, Lanchares E, et al. Why is percutaneous nephroscopy still performed with the patient prone? *J Endourol* 1990;**4**:265–8.
- [10] Ibarluzea G, Scoffone CM, Cracco CM, Poggio M, Porpiglia F, Terrone C, et al. Supine Valdivia and modified lithotomy position for simultaneous antegrade and retrograde endourological access. *BJU Int* 2007;**100**:233–6.
- [11] Falahatkar S, Moghaddam AA, Salehi M, Nikpour S, Esmaili F, Khaki N. Complete supine percutaneous nephrolithotripsy comparison with the prone standard technique. *J Endourol* 2008;**22**:2513–7.
- [12] Turner CD, Anderson J, Gerber GS. Improved patient positioning for percutaneous nephroscopic procedures using a surgical saddle. *J Urol* 2000;**163**:199–200.
- [13] Smith AD. *Smith's Textbook of Endourology*. 3rd ed. West Sussex: Wiley Chichester; 2012.
- [14] Cheng MA, Todorov A, Tempelhoff R, McHugh T, Crowder C, Laurysen C. The effect of prone positioning on intraocular pressure in anesthetized patients. *Anesthesiology* 2001;**95**:1351–5.
- [15] Hunt K, Bajekal R, Calder I, Meacher R, Eliahoo J, Acheson JF. Changes in intraocular pressure in anesthetized prone patients. *J Neurosurg Anesthesiol* 2004;**16**:287–90.
- [16] Addla SK, Rajpal S, Sutcliffe N, Adeyoju A. A simple aid to improve patient positioning during percutaneous nephrolithotomy. *Ann R Coll Surg Engl* 2008;**90**:433–4.
- [17] El-Husseiny T, Moraitis K, Maan Z, Papatsoris A, Saunders P, Golden B, et al. Percutaneous endourologic procedures in high-risk patients in the lateral decubitus position under regional anesthesia. *J Endourol* 2009;**23**:1603–6.
- [18] Gofrit ON, Shapiro A, Donchin Y, Bloom AI, Shenfeld OZ, Landau EH, et al. Lateral decubitus position for percutaneous nephrolithotripsy in the morbidly obese or kyphotic patient. *J Endourol* 2002;**16**:383–6.
- [19] Karami H, Arbab AH, Rezaei A, Mohammadhoseini M, Rezaei I. Percutaneous nephrolithotomy with ultrasonography-guided renal access in the lateral decubitus flank position. *J Endourol* 2009;**23**:33–5.
- [20] Moraitis K, Philippou P, El-Husseiny T, Wazait H, Masood J, Buchholz N. Simultaneous antegrade/retrograde upper urinary tract access: Bart's modified lateral position for complex upper tract endourologic pathologic features. *Urology* 2012;**79**:287–92.
- [21] Papatsoris AG, Zaman F, Panah A, Masood J, El-Husseiny T, Buchholz N. Simultaneous antegrade and retrograde endourologic access: 'the Barts technique'. *J Endourol* 2008;**22**:2665–6.
- [22] Papatsoris AG, Masood J, Saunders P. Supine valdivia and modified lithotomy position for simultaneous antegrade and retrograde endourological access. *BJU Int* 2007;**100**:1192.
- [23] Lezrek M, Ammani A, Bazine K, Assebane M, Kasmaoui el H, Qarro A, et al. The split-leg modified lateral position for percutaneous renal surgery and optimal retrograde access to the upper urinary tract. *Urology* 2011;**78**:217–20.
- [24] Valdivia Uria JG, Valle Gerhold J, Lopez Lopez JA, Villarroya Rodriguez S, Ambroj Navarro C, Ramirez Fabian M, et al. Technique and complications of percutaneous nephroscopy: experience with 557 patients in the supine position. *J Urol* 1998;**160**:1975–8.
- [25] Rana AM, Bhojwani JP, Junejo NN, Das Bhagia S. Tubeless PCNL with patient in supine position: procedure for all seasons?—with comprehensive technique. *Urology* 2008;**71**:581–5.
- [26] Steele D, Marshall V. Percutaneous nephrolithotomy in the supine position: a neglected approach? *J Endourol* 2007;**21**:1433–7.
- [27] Shoma AM, Eraky I, El-Kenawy MR, El-Kappany HA. Percutaneous nephrolithotomy in the supine position. Technical aspects and functional outcome compared with the prone technique. *Urology* 2002;**60**:388–92.
- [28] Ng MT, Sun WH, Cheng CW, Chan ES. Supine position is safe and effective for percutaneous nephrolithotomy. *J Endourol* 2004;**18**:469–74.
- [29] Hopper KD, Sherman JL, Luethke JM, Ghaed N. The retrorenal colon in the supine and prone patient. *Radiology* 1987;**162**:443–6.
- [30] Tuttle DN, Yeh BM, Meng MV, Breiman RS, Stoller ML, Coakley FV. Risk of injury to adjacent organs with lower-pole fluoroscopically guided percutaneous nephrostomy: evaluation with prone, supine, and multiplanar reformatted CT. *J Vasc Interv Radiol* 2005;**16**:1489–92.
- [31] Autorino R, Giannarini G. Prone or supine: is this the question? *Eur Urol* 2008;**54**:1216–8.
- [32] Hoznek A, Rode J, Ouzaid I, Faraj B, Kimuli M, de la Taille A, et al. Modified supine percutaneous nephrolithotomy for large kidney and ureteral stones: technique and results. *Eur Urol* 2012;**61**:164–70.
- [33] Daels F, Gonzalez MS, Freire FG, Jurado A, Damia O. Percutaneous lithotripsy in Valdivia–Galdakao decubitus position: our experience. *J Endourol* 2009;**23**:1615–20.
- [34] Scoffone CM, Cracco CM, Cossu M, Grande S, Poggio M, Scarpa RM. Endoscopic combined intrarenal surgery in

- Galdakao-modified supine Valdivia position: a new standard for percutaneous nephrolithotomy? *Eur Urol* 2008;**54**:1393–403.
- [35] Falahatkar S, Asli MM, Emadi SA, Enshaei A, Pourhadi H, Allahkhah A. Complete supine percutaneous nephrolithotomy (csPCNL) in patients with and without a history of stone surgery: safety and effectiveness of csPCNL. *Urol Res* 2011;**39**:295–301.
- [36] Falahatkar S, Farzan A, Allahkhah A. Is complete supine percutaneous nephrolithotripsy feasible in all patients? *Urol Res* 2011;**39**:99–104.
- [37] Falahatkar S, Enshaei A, Afsharimoghaddam A, Emadi SA, Allahkhah AA. Complete supine percutaneous nephrolithotomy with lung inflation avoids the need for a supracostal puncture. *J Endourol* 2010;**24**:213–8.
- [38] Cormio L, Annese P, Corvasce T, De Siati M, Turri FP, Lorusso F, et al. Percutaneous nephrostomy in supine position. *Urology* 2007;**69**:377–80.
- [39] Kumar P, Bach C, Kachrillas S, Papatsoris AG, Buchholz N, Masood J. Supine percutaneous nephrolithotomy (PCNL): 'in vogue' but in which position? *BJU Int.* 2012 [Epub May 7].
- [40] Bach C GA, Kumar P, Buchholz N, Papatsoris AG, Masood J. The Barts 'flank-free' modified supine position for percutaneous nephrolithotomy (PCNL). *Urol Int*, in press.
- [41] Papatsoris AG, Kachrillas S, Howairis ME, Masood J, Buchholz N. Novel technologies in flexible ureterorenoscopy. *Arab J Urol* 2011;**9**:41–6.
- [42] Papatsoris AG, Skolarikos A, Buchholz N. Intracorporeal laser lithotripsy. *Arab J Urol*, in press. <http://dx.doi.org/10.1016/j.aju.2012.02.006>.
- [43] Jeong IGKT, Bang JK, Park J, Kim W, Hwang SS, Kim HK, Park HK. Association between metabolic syndrome and the presence of kidney stones in a screened population. *Am J Kidney Dis* 2011;**38**:3–8.
- [44] Wu P, Wang L, Wang K. Supine versus prone position in percutaneous nephrolithotomy for kidney calculi: a meta-analysis. *Int Urol Nephrol* 2011;**43**:67–77.
- [45] Liu L, Zheng S, Xu Y, Wei Q. Systematic review and meta-analysis of percutaneous nephrolithotomy for patients in the supine versus prone position. *J Endourol* 2010;**24**:1941–6.