



## **Lower Limb Varicose Veins's Clinical Profile and Management**

**C. Z. Perdeshi<sup>1</sup>, Kustub A. Kulkani<sup>1\*</sup>, Revendra N. Yadav<sup>1</sup>,  
Mayur Nagwakar<sup>1</sup> and Niten H. Patil<sup>1</sup>**

<sup>1</sup>*Surgery Department, Krishna Institute of Medical Sciences Karad-415110, Maharashtra, India.*

### **Author's contribution**

*This work was carried out in collaboration among all authors. All authors read and approved the final manuscript.*

### **Article Information**

DOI: 10.9734/JPRI/2020/v32i3030894

#### Editor(s):

(1) Dr. Rahul S. Khupse, University of Findlay, USA.

#### Reviewers:

(1) Denyan Mansuroglu, Yeni Yuzyil University, Turkey.

(2) Hasan Ekim, Bozok University, Turkey.

Complete Peer review History: <http://www.sdiarticle4.com/review-history/62180>

**Original Research Article**

**Received 22 August 2020**

**Accepted 27 October 2020**

**Published 23 November 2020**

### **ABSTRACT**

The lower limbs' venous system has the pressure of posture, and blood has to be pushed against gravity into the heart cavity. This issue is generally approached either by a cautious approach or by surgical interference, all of which are constrained. Attempts to study different clinical manifestations of varicose veins are being made in the present study. The overall number of 50 varicose vein patients was analysed and the study results were reported. Varicosity veins of the lower limb is a fairly normal pathological entity. In the 20-50 age range, the condition is more common. The main modality of the procedure is surgery. The most common technique performed is Saphenofemoral flush ligation with stripping.

*Keywords: Varicose veins; long saphenous vein; lower limbs; venous.*

### **1. INTRODUCTION**

Varicose veins are a widespread medical condition found in at least 10 percent of the general population [1]. Symptoms of varicose

veins range from asymptomatic varicose veins to more extreme symptoms such as ulceration and bleeding. The care choices for Varicose Veins are Trendelenburg, Shaving, Subfascial Perforator Ligation, Laser, Sclerotherapy,

\*Corresponding author: E-mail: [Kulkarni.k@aol.com](mailto:Kulkarni.k@aol.com);

Subfascial Endoscopic Perforator Operation & Radiofrequency Ablation. More invasive techniques have been substituted for minimally invasive treatments in the recent years [2-4]. The quest for more reliable ways to detect and treat varicose veins and to avoid and control their complications continues, and this thesis aims to study the spread, anatomy, clinical characteristics, various testing types, and the overall management of varicose veins in the lower limb.

## 2. AIMS AND OBJECTIVES

To study the distribution, anatomy and clinical symptoms of lower-limb varicose veins in rural areas. To efficiently study the different types of investigation and treatment of varicose veins in the lower limbs and to reduce complications.

## 3. MATERIALS AND METHODS

The study included all patients admitted with lower limb varicose veins from October 2014 to June 2016 in the surgical department of KIMS, Karad. Total number of patient included in the study were 50. The patients who were admitted to hospital & assessed by taking comprehensive history were included in the study after doing extensive clinical evaluation. The results have been reported in clinical proforma.

## 4. OBSERVATION & RESULTS

Varicose veins tend to be common in general populations, but the incidence of hospital attendance does not project a true occurrence fig. The hospital-populated population is only the tip of the iceberg. The epidemiological research

may give the general population its true appearance. A total of 50 patients (55 numbers of organs) with primary varicose veins admitted to surgery at the Krishna Institute of Medical Sciences, Karad, were examined and the following findings were reported and analysed.

As shown in Fig. 1, out of a total of 50 patients, 16 (32%) cases were female. In contrast to western research, it is very poor. The females were seeking medication for complications because of varicosities rather than aesthetic causes. Probably Indian women cover their limbs with saree and are therefore, not too bothered by the presence of dilated veins.

As shown in Fig. 2, most of the patients were under 50 years in the study. Therefore, it cab be said that this is the disease that impacts the society's youth and bread-earning members.

## 5. DISCUSSION

Lower extremity varicosity is a typical clinical concern. Varicosity often starts early in life, but due to venous hypertension take a silent path for a variable period of time before symptoms occur.

Recent trends like Endovenous laser ablation, Endovenous radio frequency ablation, SEPS, Endovenous LSV stripping and valve grafting have revolutionized the patient care. The great saphenous vein, in the thigh has branches of medial femoral cutaneous nerve accompanying and in the distal two-thirds of the calf, saphenous nerve is anterior to the vein. Lymphatics are its close accompaniments throughout the course of the vein [5,6].

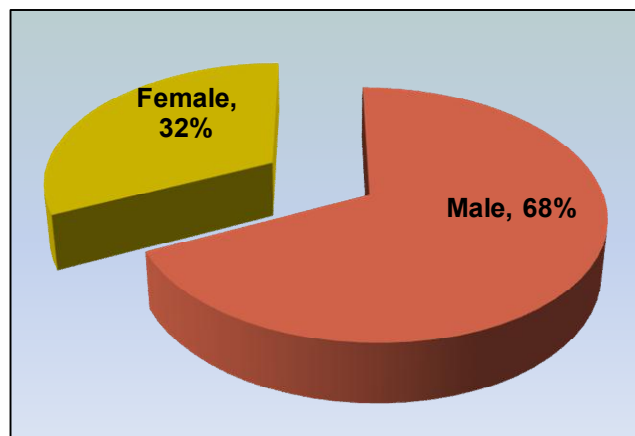
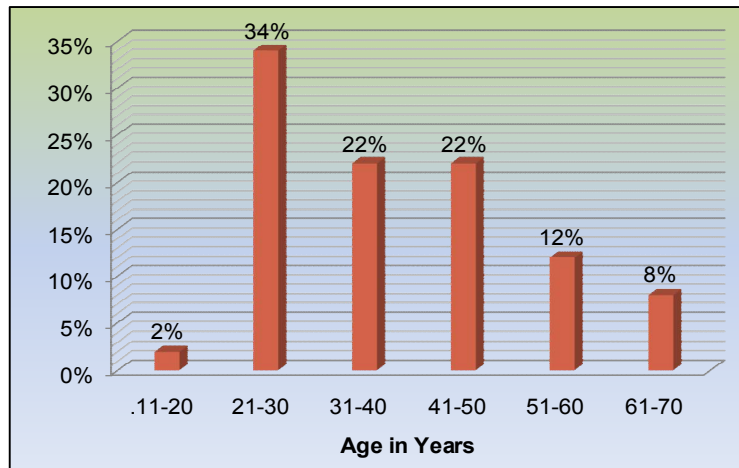


Fig. 1. Sex distribution



**Fig. 2. Age distribution**

The lower limb veins carry deoxygenated blood towards the heart. These are the low-pressure channels having larger cross sectional area. The pressure at the post capillary venules is about 20mmHg at rest. About 60-75% of the blood volume is contained within the veins. It originates in the ankle from the medial marginal vein of the arch of the dorsal vein. In the leg, it has few tributaries, which connects GSV with Short saphenous vein and deep veins [7].

Surface veins have smooth muscles in their walls that contract in response to direct stimulus or in response to cold, warm and drugs. Whereas deep veins do not have muscle in their walls making them more or less passive reservoir of blood. Blood entering the superficial veins in the leg does not travel all the way up to the groin in the superficial system. Blood gets sucked into the deep system through the nearest perforator when the calf muscle relaxes after contraction. The presence of delicate but extremely strong bicuspid valves in the superficial and deep veins, allows blood flow only towards the heart [8]. An expanded sinus at the site of each valve allows the valves to open widely without making contact with the venous wall. Thus, when venous flow starts to reverse, rapid valve closing is allowed. The deep veins contain more valves than superficial veins. Valves are present in the venules as small as 0.15mm in diameter. In all areas of the leg, valve cusps are oriented to direct flow centrally and to prevent reflux of venous blood [9].

In relation to long saphenous vein in the thigh usually there are 3-5 perforators in the thigh. These are called as Dodd's perforators. There is

a large constant perforating vein, which begins in the Long saphenous vein or usually one of its tributaries about the middle to lower third of thigh and ends in the femoral vein in the adductor canal (Huntarian perforator). At the ankle the perforating veins at the ankle are called as ankle perforators of May or Kuster. They are situated about 2, 4 and 6 cm from the tip of the medial malleolus [10].

In relation to small saphenous vein there is one large constant external perforating vein, which joins the small saphenous vein to the posterior tibial vein. This vein is called the Lateral or External ankle-perforating vein. Other perforating veins may be situated 2 and 7 inches above the tip of lateral malleolus. There is also a mid-calf perforating vein, draining directly into the soleus sinusoids in about 25% of people [11]. In case of varicose veins due to reflux of blood / obstruction in the superficial or deep veins the pressure in the superficial veins fails to fall and is sustained even during walking. This sustained rise in the pressure of superficial venous system is known as ambulatory venous hypertension and this eventually leads to skin changes seen in venous disorders.

Bleeding from varicose veins may be more common than generally thought. The initial treatment of bleeding episodes should consist of compression of the bleeding vessel rather than suture ligation. Injection Sclerotherapy can then be performed for permanent obliteration of the thin walled veins and prevention of further bleeding. Treatment should address the entire incompetent venous system rather than just the bleeding site [12].

According to Pares et al. [13] incompetent superficial veins and perforators should be thoroughly removed to prevent the tendency toward recurrence. Veins that have the potential to develop varicosities should also be removed, with particular attention directed to the smaller dilated tributaries in the thighs. Calves and feet. Special care should be taken not to damage or destroy normal competent greater or lesser saphenous veins, because they may be needed for future vascular bypass operations.

The study also concluded that lower limb symptoms are extremely common in the general population, whether varices are present or not. Significant proportion of the patients request treatment for cosmetic reasons only. Hence, a detailed assessment is needed before treatment. Failure to assess the patients adequately will result in poor patient satisfaction and possibly wrong procedure performed. In the age range aged 20-50 years, varicose veins are more prevalent [14,15]. Therefore it affects social issues of bread-earning members of society. In the present study, about 80 percent of the patients were in this age group.

## 6. CONCLUSION

Our research reveals that the varicose veins in lower limbs is greater in younger age groups. The family history of lower limb varicose veins is an significant risk factor for the occurrence of lower limb varicose veins. Long standing jobs are important predictive factors in the development of varicose veins of the lower limbs. Varicose veins mostly include the long saphenous system due to saphenofemoral and perforator negligence. Much patients have varicose vein complications. Duplex ultrasound is the examination of choice.

## CONSENT

It is not applicable.

## ETHICAL APPROVAL

It is not applicable.

## COMPETING INTERESTS

Authors have declared that no competing interests exist.

## REFERENCES

1. Rabe E, Partsch H, Hafner J, Lattimer C, Mosti G, Neumann M et al. Indications for

- medical compression stockings in venous and lymphatic disorders: An evidence-based consensus statement. *Phlebology*. 2018;33(3):163-84.
2. Illig KA, Rhodes JM, Dewese J. venous and lymphatic disease: a historical review. In *handbook of venous disorders: Guidelines of the American Venous Forum Third Edition*. 2008;26:1.(CRC Press).
3. Gloviczki P. *Handbook of venous and lymphatic disorders: Guidelines of the American Venous forum*. CRC Press; 2017.
4. S. Das. *A manual on clinical surgery examination of varicose veins*; 6th edition. 2004;73-79.
5. Rose SS, Bergan JJ, Goldman MP. "Historical development of varicose vein surgery. In *varicose veins and Telangiectasia, Diagnosis and treatment*". Quality Medical Publishing, St.Louis; 1993.
6. Goldman MP. "Sclerotherapy, Treatment of varicose and telangiectatic leg veins", 2nd edition, Mosby, St.Louis; 1995.
7. Blair A.Keagy, Robert R Mendes, Josef E Fischer, Lippincott, Williams, Wilkins. "superficial venous pathology and therapies" *Mastery of surgery*, 5th edition. 2009;2:2233-2242.
8. Uema RT, Dezotti NR, Joviliano EE, Dalio MB, Moriya T, Piccinato CE. A prospective study of venous hemodynamics and quality of live at least five years after varicose vein stripping. *Acta cirurgica brasileira*. 2013 Nov;28(11):794-9.
9. Giancesini S, Obi A, Onida S, Baccellieri D, Bissacco D, Borsuk D et al. *Global guidelines trends and controversies in lower limb venous and lymphatic disease: Narrative literature revision and experts' opinions following the WINter international meeting in Phlebology, Lymphology & Aesthetics*. *Phlebology*. 2019;34(1\_suppl):4-66.
10. Kim R, Lee W, Park EA, Yoo JY, Chung JW. Anatomic variations of lower extremity venous system in varicose vein patients: Demonstration by three-dimensional CT venography. *Acta Radiologica*. 2017;58(5):542-9.
11. Black CM. *Anatomy and physiology of the lower-extremity deep and superficial veins. Techniques in Vascular and Interventional Radiology*. 2014;17(2):68-73.

12. Lee BB, Nicolaidis AN, Myers K, Meissner M, Kalodiki E, Allegra C, Antignani PL, Baekgaard N, Beach K, Belcaro G, Black S. Venous hemodynamic changes in lower limb venous disease: the UIP consensus according to scientific evidence. *Int Angiol.* 2016;35(3):236-352.
13. Pares JO, Juan J, Tellez R, Mata A, Moreno C, Quer FX, Suarez et al. Varicose vein surgery: stripping versus the CHIVA method: a randomized controlled trial. *Annals of surgery.* 2010;251(4):624-31.
14. Scott G, Mahdi AJ, Alikhan R. Superficial vein thrombosis: A current approach to management. *British journal of haematology.* 2015;168(5):639-45.
15. Gloviczki P, Comerota AJ, Dalsing MC, Eklof BG, Gillespie DL, Gloviczki ML et al. The care of patients with varicose veins and associated chronic venous diseases: Clinical practice guidelines of the society for vascular surgery and the American Venous Forum. *Journal of vascular surgery.* 2011;53(5):2S-48S.

© 2020 Perdeshi et al.; This is an Open Access article distributed under the terms of the Creative Commons Attribution License (<http://creativecommons.org/licenses/by/4.0>), which permits unrestricted use, distribution, and reproduction in any medium, provided the original work is properly cited.

*Peer-review history:*  
*The peer review history for this paper can be accessed here:*  
<http://www.sdiarticle4.com/review-history/62180>