



# Hysteroscopic Embryo Transfer or Implantation- Experience of a Decade: An Alternative Objective and Reliable Method for Embryo Transfer (HEED) and Implantation (SEED)

Michael Kamrava<sup>1\*</sup> and Mei Yin<sup>1</sup>

<sup>1</sup>WC IVF Clinic, inc., 325 N Maple Drive, Unit 5731, Beverly Hills, CA 90210, USA.

## Authors' contributions

*This work was carried out in collaboration between both authors. Both authors read and approved the final manuscript.*

## Article Information

DOI: 10.9734/BJMMR/2015/15395

### Editor(s):

- (1) Franciszek Burdan, Experimental Teratology Unit, Human Anatomy Department, Medical University of Lublin, Poland and Radiology Department, St. John's Cancer Center, Poland.
- (2) Oswin Grollmuss, Head of Department of Pediatric and Adult Resuscitation Congenital Heart of Centre Chirurgicale Marie Lannelongue, University Paris XI, France.

### Reviewers:

- (1) A. O. Adeniji, Obstetrics & Gynaecology, Ladoko Akintola University of Technology, Nigeria.
  - (2) Wael Sabry Nossair, Obstetrics and gynaecology department, Zagazig University, Egypt.
  - (3) Magdy Abdelrahman Mohamed, OB/GYN department, Sohag University, Egypt.
- Complete Peer review History: <http://www.sciencedomain.org/review-history.php?iid=906&id=12&aid=7637>

Clinical Practice Articles

Received 24<sup>th</sup> November 2014  
Accepted 23<sup>rd</sup> December 2014  
Published 5<sup>th</sup> January 2015

## ABSTRACT

**Aims:** Here we present early experience using HEED and SEED along with a description of these procedures in more detail. There is also a new look at the endometrial cavity and the placement of embryo transfer or implantation while under direct visualization.

**Study Design:** Retrospective non-randomized and uncontrolled case series.

**Place and Duration of Study:** West Coast IVF Clinic, Inc. and LA IVF Lab, LLC, Beverly Hills, CA, USA, between June, 2002 and June, 2011.

**Methodology:** Embryo transfer was done using a mini flexible hysteroscope with an articulating tip. This was accomplished by either placing the embryo gently on the surface of the endometrium (HEED) in 35 patients undergoing IVF, or embedding the embryo just beneath the endometrial surface (SEED) in 24 patient starts using egg donation. Once pregnancy was confirmed with a positive serum hCG, they were followed up with transvaginal ultrasounds and serial serum hCG's

\*Corresponding author: Email: [drk@wcivf.com](mailto:drk@wcivf.com);

in the first trimester. They were then referred to their local obstetricians and final outcomes were recorded after deliveries.

**Results:** There were a total of 35 patients in the early (days 2 or 3) embryo transfer group (HEED) which resulted in 16(46%) total pregnancies, which included 2 biochemical pregnancies, 2 ectopics, 5 spontaneous miscarriages, and 3 multiple pregnancies. There were 7 (20%) live births. In the second group of patients with day 5 or 6 embryo implantations (SEED), there were a total of 24 patient starts, with 16(67%), 4, 0, 5, and 4 total, biochemical, ectopic and multiple pregnancies respectively. There were 7(29%) live births.

**Conclusion:** Hysteroscopic embryo transfer or implantation may increase successful pregnancies and decrease risks and side effects from IVF procedures. Further prospective, controlled and randomized studies are needed to determine effectiveness of these procedures.

*Keywords: HEED; SEED; IVF; hysteroscopy; embryo implantation; embryo transfer.*

## ABBREVIATIONS

*HEED: Hysteroscopic Endometrial Embryo Transfer; SEED: Subendometrial Embryo Delivery.*

## 1. INTRODUCTION


Over the last 35 years since the birth of the first human IVF pregnancy, major progress has been made in different components of IVF procedures [1-6]. However, there is a great difference of approximately 85% between normal embryo development and pregnancy rate [7]. This failure rate suggests that the embryo transfer stage is a key step to successful live pregnancy rates in assisted reproductive technology (ART) [8].

Traditionally, embryo transfer is done by using a catheter that is introduced into the uterus guided by a feeling of touch that is dependent on the individual operator's past experience. Although routine use of ultrasound to increase pregnancies remains controversial [9-13], a fixed distance from uterine fundus and varying lengths of insertion into the uterine cavity have been suggested with or without the use of ultrasound. Other factors implicated in the low pregnancies from IVF include: Non-tactile uterine contractions, embryos falling out of the uterine cavity into the cervix, bloody or mucus plugs on the catheter tip, bacterial contamination of the catheter, and embryos that were not expelled out of the transfer catheter [14]. Furthermore, other yet undiscovered factors responsible for embryo attachment and implantation are also of utmost importance in achieving pregnancies from healthy embryos [15-18]. Since the initial success with endoscopic embryo implantation (SEED) [19-21], endoscopic embryo transfers were subsequently extended to the earlier stages of embryo development especially in patients with advanced age or poor responders, for direct transfers onto the endometrium (HEED).

## 2. MATERIALS AND METHODS

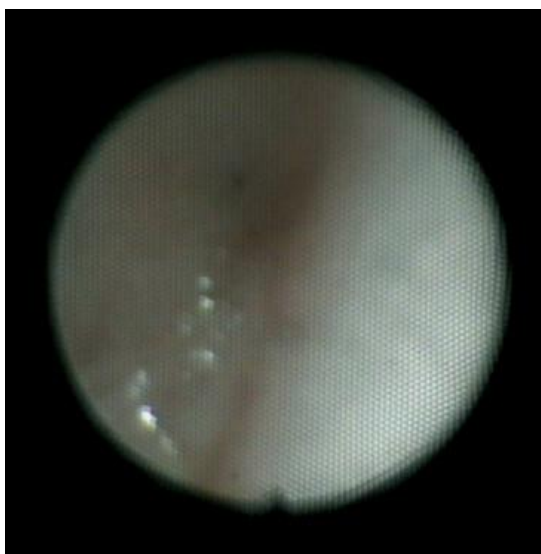Prior to the procedures, informed consent regarding traditional embryo transfer versus hysteroscopic embryo transfer or implantation were obtained from all patients. The techniques for the two procedures, HEED and SEED (Hysteroscopic Endometrial Embryo Deposition) have been previously described [19-21].

Uterine distention was achieved using nitrogen gas via a hysteroscopy insufflator. The catheter used in these procedures were initially made by Cook OB/GYN™, Spencer, Indiana USA and subsequently made by IVF Scientific, Beverly Hills, CA 90212 USA (Fig. 1).

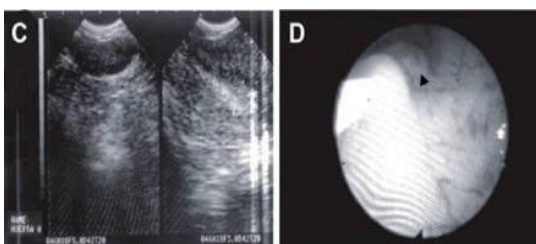


**Fig. 1. Flexible KAM hysteroscopic embryo delivery catheter (HEED or SEED), (IVF Scientific, Inc. Beverly Hills, CA, USA)**

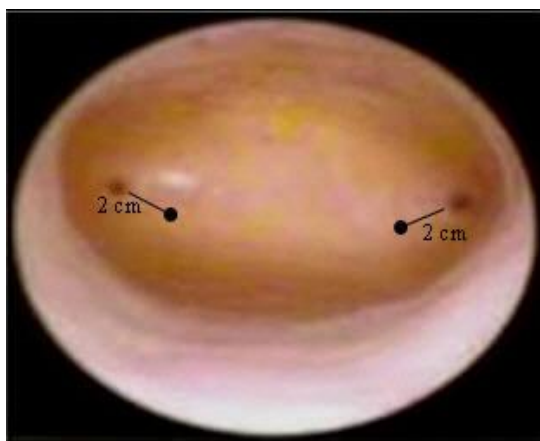
The loading catheter is shown in Fig. 1. Endometrial placement of embryos is shown in Figs. 2, 3 and 4.



**Fig. 2. Placement of embryo(s) under hysteroscopic guidance for HEED; arrow points to the tip of the catheter; catheter tip at 8 o'clock position**



**Fig. 3C and D. Placement of embryo(s) under hysteroscopic guidance for SEED; arrow points to the tip of the catheter; catheter entry at 8 o'clock position**



**Fig. 4. Endometrial places of embryo delivery**

### 3. RESULTS

The combined results are shown in Tables 1, 2 and 3. There were a total of 35 patients in the early (Days 2 or 3) embryo transfer group (HEED) which resulted in 16 (46%) total pregnancies, with 2 biochemical pregnancies, 2 ectopics, 5 spontaneous miscarriages, and 3 multiple pregnancies. There were 7 (20%) live births. In the second group of patients with day 5 or 6 embryo implantations (SEED), there were a total of 24 patient starts, with 16(67%), 4, 0, 5, and 4 total, biochemical, ectopic and multiple pregnancies respectively. There were 7(29%) live births.

### 4. DISCUSSION

There has been little change in embryo transfer technique using a catheter to blindly guide by feel and touch into the uterine cavity and then ejecting the embryo(s). Gamete intra-fallopian transfer (GIFT), zygote intra-fallopian transfer (ZIFT), pronuclear stage transfer and Embryo Intrafallopian Transfer (EIFT) [22-29] require invasive surgical procedures done under general anesthesia. Although ultrasound guided ET was desired to improve successful pregnancy outcomes and reduce side effects, it has been received with mixed results [30-42]. It also requires simultaneous coordination of two professionals, the clinician who performs the transfer and the ultrasound technician [37]. Furthermore, with the transmyometrial technique, the needle has to go through the myometrium first and then be inserted into the endometrium or released onto the endometrial surface. The procedure is more invasive than going through the natural opening of the cervix. Consistent and accurate positioning of the catheter would be difficult with the mobile uterus and hyperstimulated ovaries. In addition, myometrial invasion would be more likely to produce involuntary uterine contractions and bleeding that although cannot be seen nor verified with high accuracy by ultrasound, could have deleterious effects on final pregnancy outcome [43,44]. In order to compensate in part for luteal phase defects and other yet undiscovered factors that may interfere with embryo adherence, penetration or implantation clinicians transfer more embryos. By mechanically inserting the embryo into the endometrium using SEED technique, problems associated with the maternal receptivity may become a moot point [18].

**Table 1. Pregnancy outcomes from HEED**

Pregnancy outcomes	Day 2 transfer	Day 3 transfer	Combined
Patients started	22	13	35
Total pregnancy/Started	9	7	16(46%)
Biochemical pregnancies	2	0	2
Ectopic pregnancies	1	1	2
Spontaneous abortions	3	2	5
Multiple pregnancies	2	1	3
Live/Started	3	4	7(20%)

**Table 2. Pregnancy outcomes from SEED**

Pregnancy outcomes	Day 5 implantation	Day 6 implantation	Combined
Patients started	14	10	24
Total pregnancy/Started	8(57%)	8(80%)	16(67%)
Biochemical pregnancies	2	2	4
Ectopic pregnancies	0	0	0
Spontaneous abortions	2	3	5
Multiple pregnancies	4	0	4
Live/Started	4 (29%)	3 (30%)	7 (29%)

**Table 3. Pregnancy outcomes from combined HEED and SEED**

Pregnancy outcomes	Combined
Patients started	59
Total pregnancy/Started	32
Biochemical pregnancies	6
Ectopic pregnancies	2
Spontaneous abortions	10
Multiple pregnancies	7
Live/Started	14(24%)

After the initial success with SEED [19], attention was focused on a better prognostic group of patients, i.e. egg donors [20]. Hysteroscopic SEED virtually eliminated ectopic pregnancies (tubal, placenta previa, cervical, or heterotopic) from embryo transfers that occurred in approximately 8-10% of high risk pregnancies [11,45,46]. Lost embryos were also minimized as the embryo(s) was implanted into the endometrium and not left to float within the uterine cavity. Using the flexible mini-hysteroscope affords an objective and accurate confirmation of the placement of the embryo that is reliable and should make the procedure replicable with more consistent and improved results. In patients with advanced age, low ovarian reserve or poor responders, a day 2 or 3 embryo transfer using HEED technique is more desirable as the in vitro conditions may not be optimal for the extended culture survival of the embryos. In situations where there are many high quality embryos to choose from, allowing the embryos to reach the blastocyst stage prior

to transfer has gained more acceptance [45,46]. This natural selection of the healthier embryos would make the final embryo selection for transfer easier and allow for a less number of embryos to be transferred [47,48]. This is compatible with the results in this report showing no multiple pregnancies from day 6 implantations (SEED) (Table 1).

Hysteroscopic embryo transfer, whether by HEED or SEED, is objective and reproducible. Since involuntary uterine contractions are known to decrease embryo retention and implantation [43,44,49,50], using the endoscopic approach would be invaluable at detection of contractions prior to actual release of the embryo(s). In these situations, embryo transfer is aborted and the embryo(s) are frozen and stored for future replacement under more favorable conditions. In addition, embryo transfer under direct visualization allows for visual confirmation of release of the very low volume of transfer fluid [8,51,52] and a more precise placement of embryo(s). The ability to visualize the uterine cavity through an endoscope at time of embryo transfer is particularly important in patients with uterine fibroids, adenomyosis and intrauterine adhesions as the flexible and articulating tip of the scope can be easily maneuvered in the gaseous space. In addition, multiple suitable areas for implantation can be identified (Fig. 4).

The disadvantage and risk of this technique is possible endometrial injury with the scope. Since the uterine cavity is distended prior to scope

entry, the risk is less than blind and ultrasound guided transfers [53]. Additionally, direct visualization allows one to place the embryo at a different and non-traumatized location if endometrial injury is noted. The major drawback to its acceptance is that hysteroscopy will increase the total cost of the procedure. However, the small increase in cost is well worth the despair, agony, and further additional cost of repeat IVF's to achieve a successful pregnancy.

## 5. CONCLUSION

Hysteroscopic embryo delivery provides a visually confirmed technique for embryo placement. It allows for a targeted positioning of the embryo(s), which may increase live delivery rate and decrease untoward side effects from embryo transfer. Hence, reductions in multiple pregnancies can be focused on selecting the healthiest single embryo for transfer. Attention to detail in loading the embryo(s) [21] and direct visual placement of embryo(s) away from both internal cervical os and the junction of endometrium with endosalpingeal epithelium (Fig. 4), will minimize ectopic pregnancies in various anatomical locations. SEED is especially appealing in patients with prior tubal pregnancies and failed IVF. Additionally, patients will feel more at ease because they can simultaneously see the procedure on a live video monitor while undergoing treatment. A quicker successful pregnancy outcome will also decrease the cost to the patient because it will decrease the number of attempts necessary using IVF procedures in order to achieve a successful singleton pregnancy [54].

## ETHICAL APPROVAL

Both authors hereby declare that all experiments have been examined and approved by the appropriate ethics committees and have therefore been performed in accordance with the ethical standards laid down in the 1964 Declaration of Helsinki.

## ACKNOWLEDGMENTS

Supported by: West Coast IVF clinic, Inc. and LA IVF Lab, LLC, Beverly Hills, CA USA. The project was also partially supported by a generous funding from Organon®. The authors wish to thank Soheila Kamrava, Michelle Kamrava, and Mitchell Kamrava for their invaluable support and understanding during preparation of this report.

## COMPETING INTERESTS

Michael Kamrava is the inventor of KAM catheter and is a consultant to IVF Scientific, Inc.

## REFERENCES

1. Gardner DK, et al. Culture and transfer of human blastocysts increases implantation rates and reduces the need for multiple embryo transfers. *Fertil Steril.* 1998;69(1):84-8.
2. Dellenbach P, et al. Transvaginal sonographically controlled follicle puncture for oocyte retrieval. *Fertil Steril.* 1985;44(5):656-62.
3. Fateh M, et al. Comparison of ultrasonographic transurethral and laparoscopic guided oocytes retrieval. *Fertil Steril.* 1986;46(4):653-6.
4. Hamberger L, et al. Laparoscopy versus ultrasound guided puncture for oocyte retrieval. *Acta Eur Fertil.* 1986;17(3):195-8.
5. Ragni G, et al. Echoguided transvaginal oocyte retrieval: Effective and easy to learn technique. *Acta Eur Fertil.* 1991;22(2):89-90.
6. Raziel A, et al. Ultrasonographic-guided percutaneous transabdominal puncture for oocyte retrieval in a rare patient with Rokitansky syndrome in an in vitro fertilization surrogacy program. *Fertil Steril.* 2006;86(6):1760-3.
7. Sallam HN, et al. Impact of technical difficulties, choice of catheter and the presence of blood on the success of embryo transfer--experience from a single provider. *J Assist Reprod Genet.* 2003;20(4):135-42.
8. Meldrum DR, et al. Evolution of a highly successful in vitro fertilization-embryo transfer program. *Fertil Steril.* 1987;48(1):86-93.
9. Brown JA, et al. Ultrasound versus 'clinical touch' for catheter guidance during embryo transfer in women. *Cochrane Database Syst Rev.* 2007;1:CD006107.
10. Kosmas IP, et al. Ultrasound-guided embryo transfer does not offer any benefit in clinical outcome: A randomized controlled trial. *Hum Reprod.* 2007;22(5):1327-34.
11. Baba K, et al. Three-dimensional ultrasound in embryo transfer. *Ultrasound Obstet Gynecol.* 2000;16(4):372-3.
12. Sallam HN, Sadek SS. Ultrasound-guided embryo transfer: A meta-analysis of

- randomized controlled trials. *Fertil Steril.* 2003;80(4):1042-6.
13. Drakeley AJ, et al. A randomized controlled clinical trial of 2295 ultrasound-guided embryo transfers. *Hum Reprod.* 2008;23(5):1101-6.
  14. Schoolcraft WB, Surrey WS, Gardner DK. Embryo transfer: Techniques and variables affecting success. *Fertil Steril.* 2001;76(5):863-70.
  15. Sharkey AM, Smith SK. The endometrium as a cause of implantation failure. *Best Pract Res Clin Obstet Gynaecol.* 2003;17(2):289-307.
  16. Dominguez F, et al. A combined approach for gene discovery identifies insulin-like growth factor-binding protein-related protein 1 as a new gene implicated in human endometrial receptivity. *J Clin Endocrinol Metab.* 2003;88(4):1849-57.
  17. Jokimaa V, et al. Altered expression of genes involved in the production and degradation of endometrial extracellular matrix in patients with unexplained infertility and recurrent miscarriages. *Mol Hum Reprod.* 2002;8(12):1111-6.
  18. Kabir-Salmani M, et al. Secretory role for human uterodomes (pinopods): Secretion of LIF. *Mol Hum Reprod.* 2005;11(8):553-9.
  19. Kamrava M, Yin M. Hysteroscopic Subendometrial Embryo Delivery (SEED), Mechanical Embryo Implantation. *IJFS.* 2010;4(No 1, Apr-Jun):29-34.
  20. Kamrava M, Yin Y. SubEndometrial Embryo Delivery (SEED) with Egg Donation - Mechanical Embryo Implantation in Enhancing Success of Assisted Reproduction, A. Darwish, Editor. Rijeka, Croatia: In Tech. 2012;145-154.
  21. Kamrava M, Tran L. Hysteroscopic Endometrial Embryo Delivery (HEED), in Ectopic Pregnancy, Modern Diagnosis and Management, M. Kamrava, Editor. Rijeka, Croatia: In Tech. 2011;79-86.
  22. Asch RH, et al. Gamete intra-fallopian transfer (GIFT): A new treatment for infertility. *Int J Fertil.* 1985;30(1):41-5.
  23. Asch RH. et al. Oocyte donation and gamete intrafallopian transfer in premature ovarian failure. *Fertil Steril.* 1988;49(2):263-7.
  24. Balmaceda JP, Gonzales J, Bernardini L. Gamete and zygote intrafallopian transfers and related techniques. *Curr Opin Obstet Gynecol.* 1992;4(5):743-9.
  25. Cittadini E, et al. Gamete intrafallopian transfer: Different routes of transfer. *Acta Eur Fertil.* 1988;19(4):217-20.
  26. Frederick JL, et al. Frozen zygote intrafallopian transfer: A successful approach for transfer of cryopreserved embryos. *Fertil Steril.* 1994;61(3):504-7.
  27. Pool TB, et al. Zygote intrafallopian transfer as a treatment for nontubal infertility: A 2-year study. *Fertil Steril.* 1990;54(3):482-8.
  28. Thijssen RF, et al. Successful pregnancy after ZIFT in a patient with congenital cervical atresia. *Obstet Gynecol.* 1990;76(5 Pt 2):902-4.
  29. Henriksen T, et al. Pregnancy after translaparoscopic embryo intrafallopian transfer (EIFT). *Acta Obstet Gynecol Scand.* 1987;66(8):745-6.
  30. Allahbadia GN, et al. Embryo transfer using the SureView catheter-beacon in the womb. *Fertil Steril.* 2010;93(2):344-50.
  31. Flisser E, Grifo JA. Is what we clearly see really so obvious? Ultrasonography and transcervical embryo transfer--a review. *Fertil Steril.* 2007;87(1):1-5.
  32. Flisser E, et al. Transabdominal ultrasound-assisted embryo transfer and pregnancy outcome. *Fertil Steril.* 2006;85(2):353-7.
  33. Grifo JA, et al. Programmatic implementation of blastocyst transfer in a university-based in vitro fertilization clinic: maximizing pregnancy rates and minimizing triplet rates. *Fertil Steril.* 2007;88(2):294-300.
  34. Lambers MJ, et al. The position of transferred air bubbles after embryo transfer is related to pregnancy rate. *Fertil Steril.* 2007;88(1):68-73.
  35. Tiras B, et al. Impact of embryo replacement depth on in vitro fertilization and embryo transfer outcomes. *Fertil Steril.* 2010;94(4):1341-5.
  36. Anderson RE, et al. Transvaginal ultrasound-guided embryo transfer improves outcome in patients with previous failed in vitro fertilization cycles. *Fertil Steril.* 2002;77(4):769-75.
  37. Gergely RZ, et al. Three dimensional/four dimensional ultrasound-guided embryo transfer using the maximal implantation potential point. *Fertil Steril.* 2005;84(2):500-3.
  38. Itskovitz-Eldor J, et al. Assisted implantation: Direct intraendometrial



- embryo transfer. *Gynecol Obstet Invest.* 1997;43(2):73-5.
39. Kol S. Ultrasound-guided embryo transfer-- a special role in patients with certain uterine defects. *Fertil Steril.* 2008;89(1):260.
40. Aboufotouh I, et al. Firm versus soft embryo transfer catheters under ultrasound guidance: Does catheter choice really influence the pregnancy rates? *Fertil Steril.* 2008;89(5):1261-2.
41. Abou-Setta AM. et al. Among women undergoing embryo transfer, is the probability of pregnancy and live birth improved with ultrasound guidance over clinical touch alone? A systemic review and meta-analysis of prospective randomized trials. *Fertil Steril.* 2007;88(2):333-41.
42. Miller KL, Frattarelli JL. The pre-cycle blind mock embryo transfer is an inaccurate predictor of anticipated embryo transfer depth. *J Assist Reprod Genet.* 2007;24(2-3):77-82.
43. Biervliet FP, et al. Transmyometrial embryo transfer and junctional zone contractions. *Hum Reprod.* 2002;17(2):347-50.
44. Fanchin R, et al. [Uterine contractions at the time of embryo transfer: A hindrance to implantation?]. *Contracept Fertil Sex.* 1998;26(7-8):498-505.
45. Chang HJ, Suh CS. Ectopic pregnancy after assisted reproductive technology: what are the risk factors? *Curr Opin Obstet Gynecol.* 2010;22(3):202-7.
46. Strandell A. Thorburn J, Hamberger L. Risk factors for ectopic pregnancy in assisted reproduction. *Fertil Steril.* 1999;71(2):282-6.
47. Stillman RJ, et al. Elective single embryo transfer: A 6-year progressive implementation of 784 single blastocyst transfers and the influence of payment method on patient choice. *Fertil Steril.* 2009;92(6):1895-906.
48. Sills ES, Palermo GD. Human blastocyst culture in IVF: current laboratory applications in reproductive medicine practice. *Rom J Morphol Embryol.* 2010;51(3):441-5.
49. Kovacs GT. Which factors are important for successful embryo transfer after in-vitro fertilization? *Hum Reprod.* 1999;14(10):2679.
50. Lesny P, Killick SR, Tetlow RL, Robinson J, Maguiness SD. Embryo transfer--can we learn anything new from the observation of junctional zone contractions? *Hum Reprod.* 1998;13(6):1540-6.
51. Visser DS, Fourie FL, Kruger HF. Multiple attempts at embryo transfer: Effect on pregnancy outcome in an in vitro fertilization and embryo transfer program. *J Assist Reprod Genet.* 1993;10(1):37-43.
52. Marcus SF, Brinsden PR. Analysis of the incidence and risk factors associated with ectopic pregnancy following in-vitro fertilization and embryo transfer. *Hum Reprod.* 1995;10(1):199-203.
53. Bodri D, et al. Transvaginal versus transabdominal ultrasound guidance for embryo transfer in donor oocyte recipients: A randomized clinical trial. *Fertil Steril.* 2011;95(7):2263-8, 2268.e1.
54. PGDIS. Guidelines for good practice in PGD: programme requirements and laboratory quality assurance. *Reprod Biomed Online.* 2008;16(1):134-47.

© 2015 Kamrava and Yin; This is an Open Access article distributed under the terms of the Creative Commons Attribution License (<http://creativecommons.org/licenses/by/4.0>), which permits unrestricted use, distribution, and reproduction in any medium, provided the original work is properly cited.

*Peer-review history:*

*The peer review history for this paper can be accessed here:*  
<http://www.sciencedomain.org/review-history.php?iid=906&id=12&aid=7637>