



Computed tomography-virtual cystoscopy in the evaluation of a bladder mass: Could it replace standard conventional cystoscopy?

Ahmed H. Gabr, Mohamed Elbadry, Ashraf Elsherief & Ehab R. Tawfik

To cite this article: Ahmed H. Gabr, Mohamed Elbadry, Ashraf Elsherief & Ehab R. Tawfik (2013) Computed tomography-virtual cystoscopy in the evaluation of a bladder mass: Could it replace standard conventional cystoscopy?, Arab Journal of Urology, 11:4, 369-374, DOI: [10.1016/j.aju.2013.06.007](https://doi.org/10.1016/j.aju.2013.06.007)

To link to this article: <https://doi.org/10.1016/j.aju.2013.06.007>



© 2013 Arab Association of Urology



Published online: 05 Apr 2019.



Submit your article to this journal [↗](#)



Article views: 249




View related articles [↗](#)



Arab Journal of Urology
(Official Journal of the Arab Association of Urology)

www.sciencedirect.com



ONCOLOGY / RECONSTRUCTION
ORIGINAL ARTICLE

Computed tomography-virtual cystoscopy in the evaluation of a bladder mass: Could it replace standard conventional cystoscopy?



Ahmed H. Gabr ^{a,*}, Mohamed Elbadry ^a, Ashraf Elsherief ^b, Ehab R. Tawfik ^a

^a Urology Department, Minia University, Minia, Egypt

^b Radiology Department, Minia University, Minia, Egypt

Received 13 April 2013, Received in revised form 11 June 2013, Accepted 16 June 2013

Available online 24 August 2013

KEYWORDS

Cystoscopy;
Virtual;
CT;
Bladder carcinoma;
Conventional

ABBREVIATIONS

CC, conventional cystoscopy;
3D, three-dimensional;
VC, virtual cystoscopy;
MPR, multiplanar reconstruction

Abstract Objective: To determine the role of computed tomography-virtual cystoscopy (CT-VC) in the detection and evaluation of bladder cancer, compared to standard conventional cystoscopy (CC).

Patients and methods: Twenty-five patients with a clinical presentation of a bladder mass(es) were selected from an outpatient urology clinic between May 2011 and August 2012. All patients were then assessed using multi-slice CT of the bladder, CT-VC and CC. The results were then compared amongst axial CT images, multiplanar reconstruction (MPR) images, CT-VC and CC, and compared with the pathological results.

Results: Forty lesions were found at CC in the 25 patients. MPR images had a greater sensitivity for detecting small masses of ≤ 5 mm, and for identifying the location of the masses, especially basal (100%), than had axial images. The diagnostic results varied significantly ($P = 0.031$ and 0.039) between CC and axial images.

* Corresponding author. Tel.: +20 1002557332.

E-mail address: aradwan76@hotmail.com (A.H. Gabr).

Peer review under responsibility of Arab Association of Urology.



Production and hosting by Elsevier

The difference was slightly significant ($P = 0.063$) for MPR images and was not significant ($P = 0.99$) for virtual images.

Conclusions: Compared to CC, CT-VC was much less invasive, but it was not possible to take a biopsy and provide tissue for histopathology, and it could not depict flat lesions or mucosal colour changes. Therefore, CT-VC could be considered for bladder mapping before CC, in the follow-up of patients with superficial transitional cell carcinoma after transurethral resection of the tumour, in combination with urine cytology, and for patients in whom CC is difficult or contraindicated.

© 2013 Production and hosting by Elsevier B.V. on behalf of Arab Association of Urology.

Introduction

Urinary bladder carcinoma is a common malignancy, with a worldwide age-standardised incidence rate of 10.1 per 100,000 for men and 2.5 per 100,000 for women [1]. In Egypt, bladder carcinoma is the most prevalent malignancy among Egyptian males (19%), causing 15.6% of cancer-related deaths. In Egyptian females, bladder cancer is the seventh common malignancy (3.8%), causing 3.7% of cancer-related deaths [2].

Because of this high incidence, reliable techniques for diagnosis are needed. Conventional cystoscopy (CC) remains the standard method for the diagnosis of bladder cancer, while CT and MRI are used mainly for assessing related extravesical pelvi-abdominal manifestations.

With commercially available software, virtual-reality imaging, which was developed as a result of advances in three-dimensional (3D) computer-rendering techniques with rapid image acquisition, allows interactive intraluminal navigation through any hollow viscus, imitating conventional endoscopy. This technique has been applied to many organs, including the colon, stomach and bladder, the last being referred to as virtual cystoscopy (VC) [3]. VC provides many advantages, as it offers the precise localisation of a lesion due to its wide field of view, and the detection of extravesical anatomical landmarks [4]. Despite the fact that no biopsy can be taken from the bladder mass, and that the sensitivity of VC for detecting small masses (< 5 mm) is lower, it could still be very useful and of benefit to patients with bladder masses, comparable with the results of CC [5]. Thus the main aim of the present study was to determine the diagnostic potential and the role of CT-VC for detecting and evaluating bladder cancer, compared to standard CC.

Patients and methods

Between May 2011 and August 2012, 25 patients (21 men and four women, median age 64 years, range 57–71) presented to our urology department and were selected to be included in a prospective study. The criteria for selection were that the patients complained of gross painless haematuria and had a bladder mass(es)

suspected clinically after a DRE in men or on a vaginal examination in women, and/or radiologically by pelvi-abdominal ultrasonography, or a history of bladder carcinoma.

All radiological investigations were done in the radiology department. Multi-slice CT of the abdomen and pelvis and multi-slice CT-VC were conducted as follows. For all CT examinations we used a 16-MDCT scanner with a helical thickness of 0.625 mm. Preparation included the insertion of a Foley catheter into the urinary bladder to drain residual urine. The bladder was then filled with 150–400 mL of room air through the Foley catheter, according to the capacity of the bladder and patient's tolerance. Images were taken with the patient both supine and prone. The axial CT slice images were transferred to a workstation. Multiplanar reconstruction (MPR) images were obtained in the transverse, coronal and sagittal planes; these images were produced in < 1 min. VC images were then obtained using the volume-rendering technique. The first step towards surface rendering was segmentation, through which stereoscopic images were generated of the inner wall of the bladder cavity, from the original axial images, similar to those visualised using an endoscope. For this method we used the threshold technique, which extracted the region of interest on basis of the set of thresholds. On the monitor, three windows simultaneously displayed the overall view (the 3D picture), the local view (the virtual image), and the nearest CT imaging slice, with the camera positioned as indicated. The virtual camera had three functions, simulating the translations and rotations of a real endoscope. It can be advanced along the z -axis, rotated around the z -axis and pivoted around the x -axis.

The images, for axial, MPR and virtual views, were interpreted prospectively, both separately and in combination. The size, number, location and morphological features of the lesions were evaluated. Tumour size was classified into those with a diameter of ≤ 5 mm, 6–10 mm and > 10 mm. The lesions were described as sessile, polypoid, or areas of wall thickening. A lesion was characterised as sessile when it was connected by a broad base to the bladder wall. If it was connected by a narrow stalk, and projecting into the bladder cavity, then it was defined as a polypoid lesion. An area of wall

Table 1 A comparison between axial CT supine and prone imaging findings vs CC findings.

Findings, n (%)	CC	Axial CT supine	<i>P</i>	Axial CT prone	<i>P</i>	CT-VC	<i>P</i>
<i>Mass(es)</i>							
Present	25 (100)	23 (92)		24 (96)		25 (100)	
Absent	0	2 (8)		1 (4)		0	
Number of masses	40	33		36			
One	17 (68)	19 (76)	0.5	18 (72)	0.28	18 (72)	0.63
Two	5 (20)	1 (4)	0.13	3 (12)	0.63	4 (16)	0.63
Three	0	1 (4)	0.99	1 (4)	0.99	0	–
Four	2 (8)	1 (4)	0.99	1 (4)	0.99	2 (8)	–
Five	1 (4)	1 (4)		1 (4)		1 (4)	–
<i>Location</i>							
Basal	12 (30)	9 (27)	0.28	11 (31)	0.99	11 (28)	0.99
Dome	4 (10)	4 (13)		4 (11)		4 (10)	
Right lateral	16 (40)	13 (39)	0.28	13 (36)	0.45	16 (41)	
Left lateral	8 (20)	7 (21)	0.45	8 (22)		8 (21)	
<i>Morphology</i>							
Polypoid	13 (32)	11 (33)	0.63	13 (32)	0.99	13 (33)	
Sessile	25 (63)	22 (67)	0.38	25 (63)	0.69	25 (64)	
Irregular wall thickening	2 (5)	0 (0)	0.5	2 (5)	0.5	1 (3)	
<i>Size (mm)</i>							
≤5	10 (25)	4 (12)	0.031*	4 (11)	0.039*	9 (23)	
6–10	6 (15)	4 (12)	0.5	5 (14)	0.99	6 (16)	
>10	24 (60)	25 (76)	0.99	27 (75)	0.55	24 (61)	

* Significant.

thickening was defined when there were no associated distinct masses. The time required to interpret the images was ≈10 min.

The findings of CT-VC (including axial, MPR and virtual images) and those of CC, which were taken as the reference standard, were then compared. The histological diagnoses were then correlated with these findings. The interval between CT-VC and CC was <7 days. Data were checked, coded, entered and analysed using commercially available software. McNemar's test for categorical data was used to test the significance of differences amongst the urinary bladder findings of axial CT supine images, axial CT prone

images, MPR images and CT-VC, respectively, and with the findings of CC, with $P < 0.05$ considered to indicate significant differences.

Results

The number, location, morphology and size of the bladder masses are shown in Table 1. The results showed that imaging with the patient both supine and prone was necessary to avoid missing lesions that could be hidden within the residual urine. Two lesions located on the base of the urinary bladder and one on the left lateral wall were detected only on prone images.

Table 2 The sensitivity (%) and specificity (%) of axial CT supine and prone image findings compared with CC findings.

Findings	Axial CT supine		Axial CT prone		MPR	
	Sensitivity	Specificity	Sensitivity	Specificity	Sensitivity	Specificity
<i>Location of mass</i>						
Basal	75	100	92	100	100	100
Dome	100	100	100	100	100	100
Right lateral	81	100	81	100	81	100
Left lateral	88	100	100	100	100	100
<i>Morphology</i>						
Polypoid	85	100	100	100	100	100
Sessile	88	100	88	100	96	100
Irregular wall thickening	0	0	0	0	0	0
<i>Size (mm)</i>						
≤5	40	100	56	97	67	97
6–10	67	97	67	97	83	97
>10	83	87	92	87	96	93

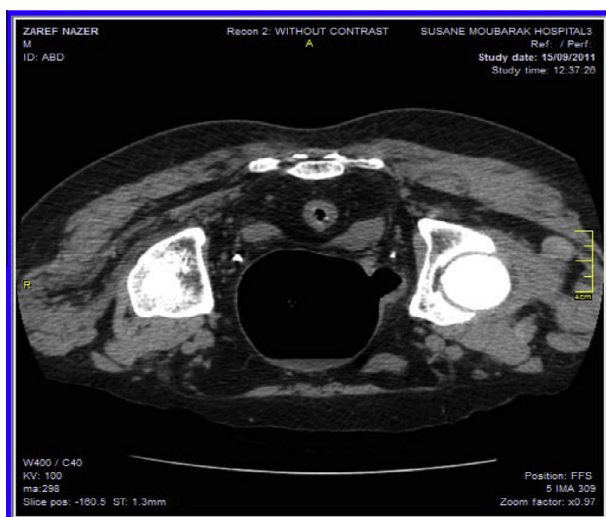


Figure 1 An axial CT image of the urinary bladder showing a small bladder diverticulum at the right lateral bladder wall, with no masses detected.

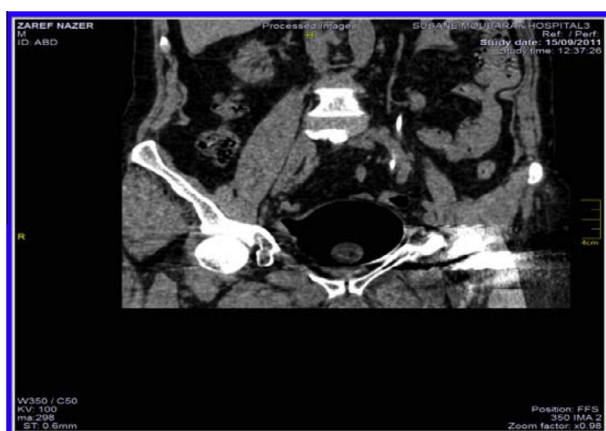


Figure 2 An MPR image of the urinary bladder showing a suspected soft-tissue lesion within the diverticulum.

Axial CT films, either supine or prone, had a low sensitivity (40% and 56%, respectively) for detecting masses of ≤ 5 mm. However, there were three masses which were > 10 mm on axial images and had a main extravesical component, so on CC they appeared to be < 10 mm because only the intraluminal component of the mass was visible on CC. Also, axial films failed to detect two areas of irregular wall thickening that were detected on CC (Table 1).

The sensitivity of MPR images was greater for identifying small masses of ≤ 5 mm (67%) than was that of axial films (40% and 56%, Table 2). Also, MPR images had a greater sensitivity for identifying the location of masses, especially basal masses (100%), than had axial films (75% and 92%; Table 2). However, MPR images also failed to detect two areas of irregular wall thickening that were detected on CC. CT-VC detected 39

lesions in the 25 patients, and all were confirmed with CC. Thirteen (33%) lesions were polypoid, 25 (64%) sessile and one was an area of bladder wall thickening. Eleven lesions were basal, four in the dome, 16 on the right lateral wall and eight on the left lateral wall. Seven patients had multiple lesions of the urinary bladder; four patients had two lesions, two had four lesions, and one had five lesions. The mean (range) size of the lesions detected was 18 (3–90) mm. Nine (23% of the total) lesions detected on CT-VC had a diameter of ≤ 5 mm, six (16%) were 6–10 mm, and 24 (61%) were > 10 mm in diameter. CT-VC failed to detect only one lesion, a basal irregular wall thickening of < 5 mm, as it was masked by the Foley catheter and detected only on CC. CT-VC was highly sensitive for detecting small masses, including those of ≤ 5 mm (90%) and 6–10 mm (100%). CT-VC was also highly sensitive for identifying the location of masses, either in the dome (100%), base (92%), right lateral (100%) or left lateral (100%), and their morphology, either polypoid (100%), sessile (100%) or irregular wall thickening (50%), compared with CC and with axial and MPR images. Table 1 also shows a comparison between the CT-VC and CC findings.

The diagnostic results differed significantly ($P = 0.031$ and 0.039 , McNemar test) between CC and axial images. The difference was slightly significant ($P = 0.063$) for MPR images and was not significant ($P = 0.99$) for CT-VC images. These results showed the advantage of CT-VC over MPR imaging, and especially over axial imaging, for detecting small bladder masses of ≤ 5 mm.

An example case is given in Figs 1–3, showing images from a 61-year-old man who presented with haematuria and pyuria, with a history of previous CC and ureteroscopy, a left JJ stent, and an accidentally discovered bladder mass, for which he had a transurethral resection. There was no mass detectable on a DRE.

Discussion

Urinary bladder carcinoma is considered the ninth most common cancer worldwide [6]. Various diagnostic methods have been developed to diagnose bladder cancer, including ultrasonography, CT and MRI. The emergence of virtual endoscopy increased the options for evaluating bladder cancer. The volumetric data obtained with CT (or MRI) can be rendered by computer to generate 3D images, and by using commercially available software, intraluminal navigation through any hollow viscus is feasible [7]. In the present study we determined the diagnostic potential and the role of CT-VC for detecting and evaluating bladder cancer, compared to standard CC.

We used air to distend the urinary bladder, as the high attenuation gradient between air and the mucosa increases the contrast between the bladder wall and the lumen, producing ideal conditions for acquiring

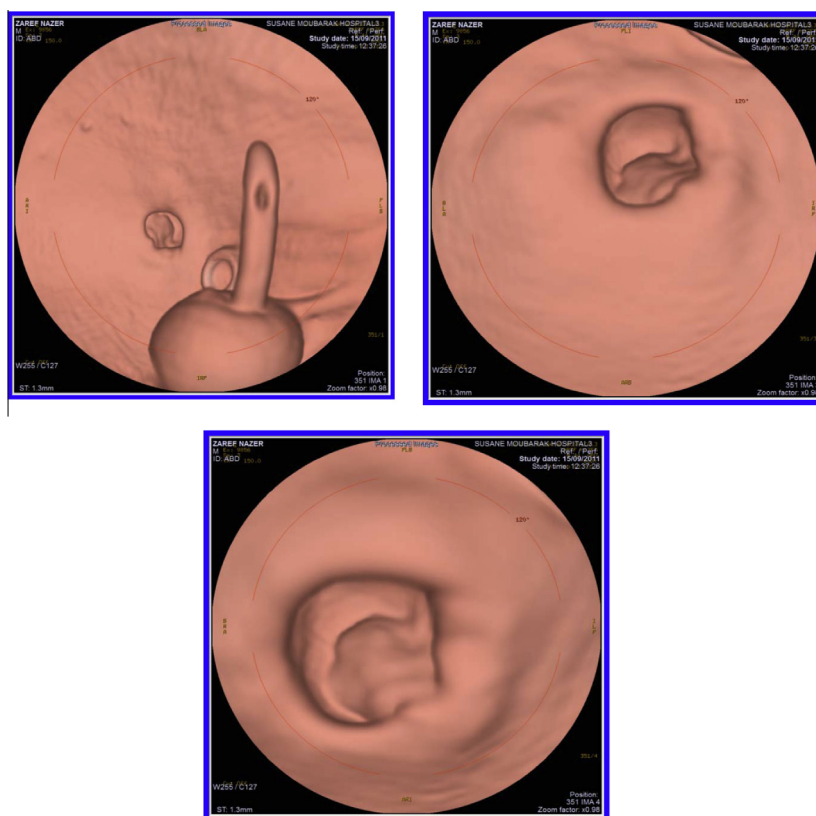


Figure 3 CT-VC of the bladder showing a diverticulum at the right lateral bladder wall, with a well-defined sessile mass within the diverticulum ≈ 9 mm long (that was confirmed by CC); the biopsy showed TCC Grade 2.

virtual images. Others [8–11] have assessed CT-VC using the air-filled bladder technique. However, this technique is relatively invasive because urethral catheterisation is associated with a risk of infection, although minimal (1–2%), when compared with CC. Also, examining the patient both supine and prone can carry another risk of increased radiation exposure. However, radiation exposure is restricted to the bladder region, and therefore it might not be considered to be an important factor. Also Tsili et al. [12] used low tube current and time settings for air-filled CT-VC to reduce the radiation risk. However, Nambirajan et al. [13] and Kim et al. [14] used CT-VC after injecting the patient with iodinated contrast material, which is considered less invasive than techniques using air to fill the bladder, because catheterisation is unnecessary. The images are taken in one position, and hence the radiation dose can be half of that used in CT-VC of an air-filled bladder. Also, it can be done as part of the CT urography, allowing a detailed assessment of the whole urinary tract. However, it has limitations, such as possible allergies to contrast media and unsuitability for uraemic patients. Another limitation of using contrast media is the presence of artefacts on virtual images that could affect image quality, if there is insufficient mixing of urine and contrast material, as in cases of bladders with marked trabeculation.

For the size (depth) of the mass, the present study showed a sensitivity of 100% for detecting bladder masses, including those of 5–10 mm, by CT-VC in all cases, and 90% sensitivity for assessing masses of ≤ 5 mm. Many studies have reported different results. Narumi et al. [8] found the detection and characterisation of masses of < 10 mm to be difficult using a 3D display of helical CT data, while Fenlon et al. [15] reported that all of the bladder masses detected at CC were visualised at CT-VC, and reported that all tumours of < 10 mm were identified, although this group did not report how many of their masses were < 5 mm. In their study, Song et al. [16] showed that VC is a practical method for detecting bladder masses of > 5 mm, but for lesions of ≤ 5 mm the detection rate was 60%. Kim et al. [17] reported an excellent agreement between VC and CC, with a high sensitivity and specificity, and their detection rate for lesions of < 5 mm was 88%. Tsili et al. [12] detected all 30 bladder lesions in 24 patients, but that study included only four lesions of < 5 mm, while Constantine et al. [11] detected 18 lesions on CT-VC, of 20 lesions with a diameter of ≤ 5 mm on CC. These different results might be attributed to the different types of CT scanners used, different parameters used during the CT examinations, and variable levels of experience in the interpretation of VC.

The present study shows that when using a combination of axial, MPR and virtual images, the evaluation is optimised, increasing the efficacy of the techniques, especially for detecting small lesions. Virtual imaging was better than MPR and axial source imaging for detecting the bladder lesions, as it was in the study by Kim et al. [14] and Constantine et al. [11]. In the present study the use of MPR and virtual imaging enabled the detection of three small tumours not seen on axial images. Constantine et al. [11] reported that the use of MPR and virtual imaging detected 11 small tumours that were not detected on axial images. Also, VC allowed an assessment of a large volume of data that improved the appreciation of 3D structures over that revealed with two-dimensional images.

In the present study there were no significant complications related to VC. To our knowledge, only one complicated case was reported in English, and was related to catheter removal at CT-VC. The absence of clinical complications confirmed the safety of the technique. Some disadvantages of VC were apparent during the study. VC cannot depict mucosal colour changes (like leucoplakia), that can be detected only on CC. This was also reported by Song et al. [16] and Heinz-Peer et al. [18]. In addition, the calcifications associated with masses were seen only on the axial and MPR images, but not on the virtual images, due to the threshold selection optimised to detect soft-tissue abnormalities. The same finding was reported by Song et al. [16]. The present study was our experience with CT-VC, but other studies with more patients will be needed to evaluate the effectiveness of the procedure. The main limitations to the study included cost, as virtual endoscopy requires specialised software and hardware that are expensive, and the inability to identify the origin and nature of the bladder masses.

In conclusion, compared to CC, CT-VC is much less invasive, with minimum discomfort and risk for the patients, especially in that there are no requirements for anaesthesia. It can be used to image the bladder in several planes and provides intraluminal viewing of the bladder from any angle. However, it is not possible to take a biopsy and thus provide tissue for histopathology. Also, it cannot be used to depict areas of irregular thickening in bladder mucosa. Therefore, it cannot totally replace the standard CC. In our opinion, the value of CT-VC could be in bladder mapping before CC, in the follow-up of patients with superficial TCC after transurethral resection of the tumour (combined with urine cytology) to lessen the frequency of follow-up CC, and cases in which CC is difficult to perform or is contraindicated.

Conflict of interest

None.

Source of funding

None.

References

- [1] Ploeg M, Aben KKH, Kiemeny LA. The present and future burden of urinary bladder cancer in the world. *World J Urol* 2009;**27**:289–93.
- [2] Ferlay J, Shin HR, Bray F, Forman D, Mathers C, Parkin DM. Estimates of worldwide burden of cancer in 2008. GLOBOCAN 2008. *Int J Cancer* 2010;**127**:2893–917.
- [3] Gualdi GF, Casciani E, Rojas M, Poletini E. Virtual cystoscopy of bladder neoplasms: preliminary experience. *Radiol Med* 1999;**97**:506–9.
- [4] Bernhardt TM, Rapp-Bernhardt U. Virtual cystoscopy of the bladder based on CT and MRI data. *Abdom Imaging* 2001;**26**:325–32.
- [5] Zhi Neng Chen et al. Application value of multi-slice spiral CT and post-processing technique in diagnosis of urologic diseases. *Zhejiang Clin Med J* 2008;**03**.
- [6] Murta-Nascimento C, Schmitz-Drager BJ, Zeegers MP, Steineck M, Kogevinas M, Real FX, et al. Epidemiology of urinary bladder cancer: from tumour development to patient's death. *World J Urol* 2007;**25**:285–95.
- [7] Calhoun PS, Kuszyk BS, Heath DG, Carley JC, Fishman EK. Three-dimensional volume rendering of spiral CT data. Theory and methods. *Radiographics* 1999;**19**:745–64.
- [8] Narumi Y, Kumatani T, Souvai Y, Kuriyama K, Kuroda C, Takahashi S, et al. The bladder and bladder tumors: imaging with three-dimensional display of helical CT data. *Am J Roentgenol* 1996;**167**:1134–5.
- [9] Fleiter TR, Merkle EM, Wisianowsky C. Virtual cystoscopy. In: Ragolla P, Sheltinga JT, Hamm B, editors. *Virtual endoscopy and related 3D techniques*. Berlin, NY: Springer; 2000.
- [10] Bernhardt TM, Krause UW, Philipp C, Allhoff EP, Rapp-Bernhardt U. Virtual cystoscopy with reduced tube current: an alternative to cystoscopy? *Fortschr Rontgenstr* 2003;**175**:1106–11.
- [11] Tsampoulas C, Tsili AC, Giannakis D, Alamanos Y, Sofikitis N, Efremidis SC. 16-MDCT cystoscopy in the evaluation of neoplasms of the urinary bladder. *AJR* 2008;**190**:729–35.
- [12] Tsili AC, Tsampoulas C, Chatziparaskevas N, Silakos A, Kalef-Ezra J, Sofikitis N, et al. Computed tomographic virtual cystoscopy for the detection of urinary bladder neoplasms. *Eur Urol* 2004;**46**:579–85.
- [13] Nambirajan T, Sohaib SA, Muller-Pollard C, Reznik R, Chinnegundoh I. Virtual cystoscopy from computed tomography: a pilot study. *BJU Int* 2004;**94**:828–31.
- [14] Kim JK, Park SY, Kim HS, Kim SH, Cho KS. Comparison of virtual cystoscopy, multiplanar reformation, and source CT images with contrast material-filled bladder for detecting lesions. *AJR* 2005;**185**:689–96.
- [15] Fenlon HM, Bell TV, Ahari HK, Hussain S. Virtual cystoscopy, early clinical experience. *Radiology* 1997;**205**:272–5.
- [16] Song JH, Francis IR, Platt JF, Cohan RH, Mohsin J, Kielb SJ, et al. Bladder tumor detection at virtual cystoscopy. *Radiology* 2001;**218**:95–100.
- [17] Kim JK, Ahn JH, Park T, Ahn HJ, Kim CS, Cho KS. Virtual cystoscopy of the contrast material-filled bladder in patients with gross hematuria. *AJR* 2002;**179**:763–8.
- [18] Heinz-Peer G, Mang T, Happel B, Latzke D. Virtual cystoscopy in detection of bladder lesions. *Med Imaging Int* 2003;**6**–9.