



# Exploring Hemophilic Pseudotumors: A Comprehensive Case Series

Anshul Tomar <sup>a++\*</sup>, Sunita Aggarwal <sup>a#</sup>, Ranvijay Singh <sup>a†</sup>,  
Soumia M <sup>a++</sup> and Anchit Aggarwal <sup>b‡</sup>

<sup>a</sup> Department of General Medicine, Maulana Azad Medical College, New Delhi, India.

<sup>b</sup> University College of Medical Sciences, New Delhi, India.

## Authors' contributions

This work was carried out in collaboration among all authors. All authors read and approved the final manuscript.

## Article Information

DOI: <https://doi.org/10.9734/ajmah/2024/v22i111112>

## Open Peer Review History:

This journal follows the Advanced Open Peer Review policy. Identity of the Reviewers, Editor(s) and additional Reviewers, peer review comments, different versions of the manuscript, comments of the editors, etc are available here: <https://www.sdiarticle5.com/review-history/125109>

Received: 14/08/2024

Accepted: 16/10/2024

Published: 19/10/2024

## Case Study

## ABSTRACT

**Introduction:** This case series investigates four hemophilic pseudotumors, which are rare but significant complications of hemophilia. All patients presented with localized swelling and pain, with imaging revealing mass-like lesions that mimicked tumors. Treatment involved a combination of surgical intervention and factor replacement therapy. The findings underscore the importance of diagnostic vigilance and highlight the necessity of a multimodal approach to manage these challenging cases effectively.

**Aim(s):** The major aim of this study is to highlight the prevalence of hemophilic complications like pseudotumors in India. Along with this, this series also aims to shed some light on the multi-disciplinary approach required to manage these complications of Hemophilia.

<sup>++</sup> Post Graduate Resident;

<sup>#</sup> Director Professor;

<sup>†</sup> Senior Resident;

<sup>‡</sup> Undergraduate Student;

\*Corresponding author: E-mail: [tdranshul@gmail.com](mailto:tdranshul@gmail.com);

**Cite as:** Tomar, Anshul, Sunita Aggarwal, Ranvijay Singh, Soumia M, and Anchit Aggarwal. 2024. "Exploring Hemophilic Pseudotumors: A Comprehensive Case Series". *Asian Journal of Medicine and Health* 22 (11):12-19. <https://doi.org/10.9734/ajmah/2024/v22i111112>.

**Study Design:** Case series.

**Methods and Materials:** 4 cases were followed at a tertiary care centre who presented with various complaints but were each linked by hemophilic pseudotumor. It takes into account the management approach in each case.

**Conclusion:** Early detection of compressive symptoms in hemophilic pseudotumors is crucial for accurate surgical planning. Recent hemorrhages should be managed conservatively, while chronic cases with pain and pressure symptoms often require surgery. Surgical intervention, though complex, is essential and should involve a multidisciplinary approach to prevent morbidity and mortality.

*Keywords:* Hemophilia; pseudotumor; medicine; surgery.

## 1. INTRODUCTION

Pseudotumors result from recurrent hemorrhages in submucosal or fibrous tissues, causing visceral or somatic swellings. This case series examines four hemophilic pseudotumors, rare yet serious complications of hemophilia. Patients presented with swelling and pain, with imaging revealing tumor-like lesions. Treatment involved surgical intervention and factor replacement therapy, highlighting diagnostic and therapeutic challenges. Despite a decline in pseudotumor cases due to advances in prophylactic care, financial limitations in developing countries still lead to a significant number of cases, requiring an interdisciplinary management approach.

We present a series of hemophilic pseudotumors which were managed with a multi-modal approach. Pseudotumors affect 1% to 2% of severe hemophiliacs (Rodriguez-Merchan, 2016), often compressing nearby structures, requiring a multidisciplinary approach. At our centre, 0.8% of patients present with pseudotumors, while 4% develop them regardless of treatment. The higher prevalence in our country stems from financial constraints, limiting prophylaxis to secondary rather than primary care. The main aim of this study is to highlight the prevalence of Hemophilia and its complications in India, different presentations of Hemophilia, and the integrated management of complications.

## 2. CASE PRESENTATIONS

**Case 1:** A 32-year-old male with severe Hemophilia A (Factor VIII <1%) presented with a progressively enlarging lump in the right lower abdomen. Initially painless, the lump became painful and developed excoriations. Neglected by the patient, it eventually caused functional limitations. On examination, the solid lump

measured 12x14 cm, was tender, non-mobile, and firm. No associated discharge was noted [Fig. 1(a)].

**Case 2:** A 21-year-old male with severe Hemophilia A presented with swelling behind the right knee, accompanied by pain and limping. The swelling, 4x5 cm, extended from the popliteal fossa to the upper third of the tibia [Fig. 2(a)]. The patient could not attend college due to discomfort. Imaging raised concerns of malignancy, but a biopsy confirmed it was a pseudotumor. Surgery was recommended.

**Case 3:** A 26-year-old male with severe Hemophilia B (Factor IX <1%) complained of abdominal dragging sensations and limping for months, eventually noticing a swelling in the right lower abdomen. Examination revealed a 6x6 cm lump in the right iliac fossa, soft to firm in consistency. The patient's symptoms affected his ability to perform daily and work-related tasks.

**Case 4:** A 17-year-old male with severe Hemophilia A presented with a dry cough for two months and an episode of hemoptysis. Examination showed decreased air entry in the left chest region without other significant respiratory findings. The patient exhibited no toxic appearance.

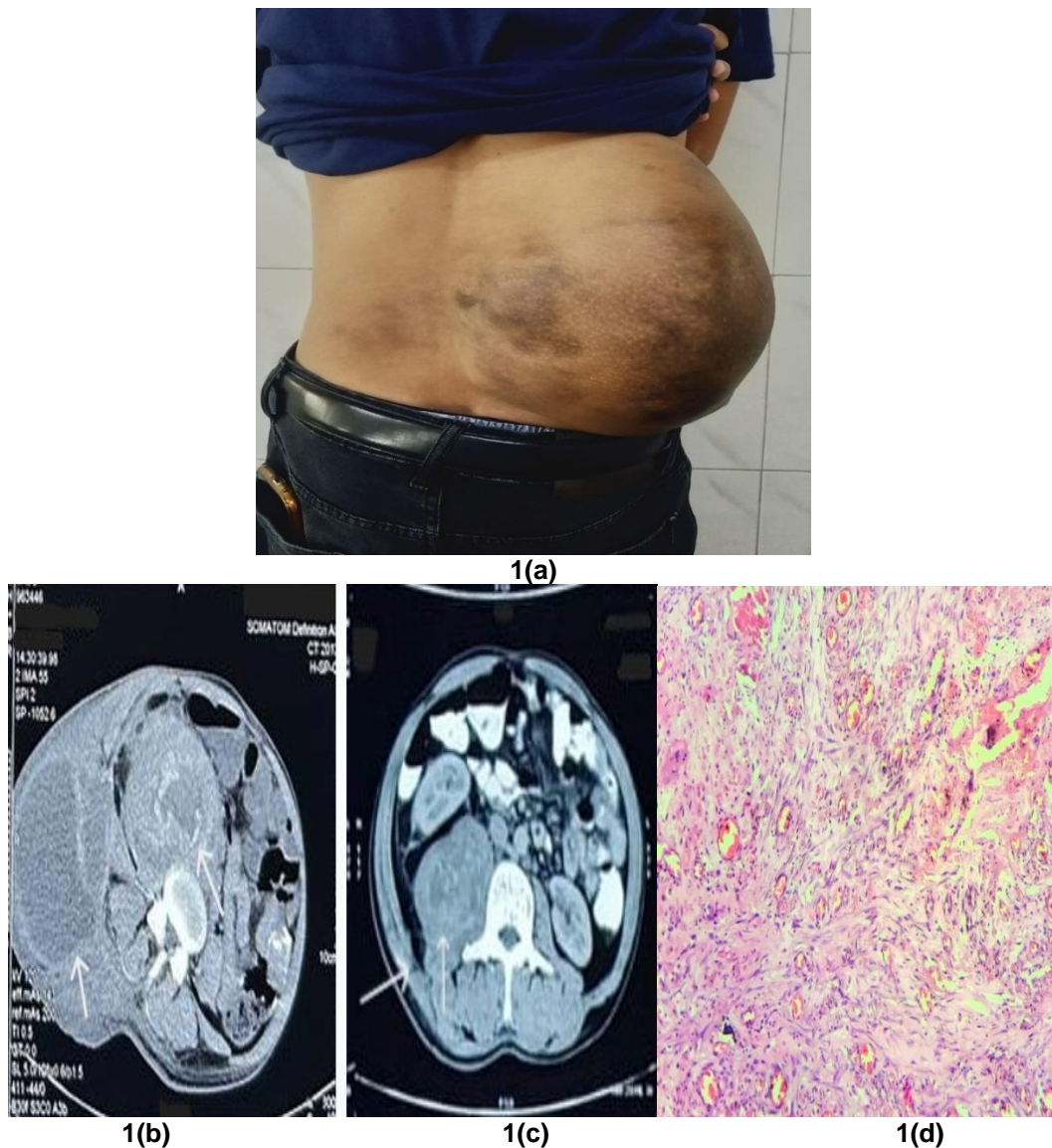
## 3. MANAGEMENT

**Case 1:** Contrast Enhanced Computed Tomography (CECT) of the abdomen revealed visceral and parietal pseudotumors with a fistulous tract. Two lumps were identified: a 25x18x7 cm parietal lump and a 20x12x5 cm visceral lump. No active bleeding vessels were present [Fig. 1(b)]. The treatment involved staged surgery, starting with the removal of the parietal pseudotumor via wide local excision and cauterization of the fistulous tract, reducing growth of the pseudotumor. The visceral

pseudotumor, near the right kidney, was not removed to avoid renal injury [Fig. 1(c)]. The histological assessment showed fibrous strands with hemorrhagic foci in between [Fig. 1(d)]. The patient received pre- and post-operative Anti-Hemophilic Factor (AHF) transfusions, as per WFH guidelines (Srivastava et al., 2020). The patient was placed on low-dose prophylaxis after his surgery, for which the patient is very compliant.

**Case 2:** The patient underwent a Magnetic Resonance Imaging (MRI) of the right knee,

revealing solid-cystic changes with hemorrhage, initially suggesting a malignancy, likely a Giant Cell Tumor. The lump measured 10x8x12 cm<sup>3</sup>[Fig. 2(b)]. To clarify the diagnosis, the swelling was resected and examined via frozen section, confirming pseudotumor. Pre-emptive radiotherapy of ten 50 cGy cycles reduced the tumor size by 5%. Despite receiving AHF prophylaxis per WFH guidelines, the tumor had invaded the joint capsule and synovial cavity and the adjacent larger popliteal vessels, leading to limb amputation. The extension of the pseudotumor was too great for the limb to



**Fig. 1. Gross, radiological and histopathological images of the first case**

1(a): The massive lump that the patient presented with; 1(b): Pre-operative image showing both the pseudotumors in situ; 1(c): Post-operative image showing successful resection of the parietal pseudotumor. The visceral one was left as such; 1(d): Microscopic image of the resected pseudotumor under 100X magnification in H&E stain showing areas of hemorrhage with interspersed collagen and fibrous tissue

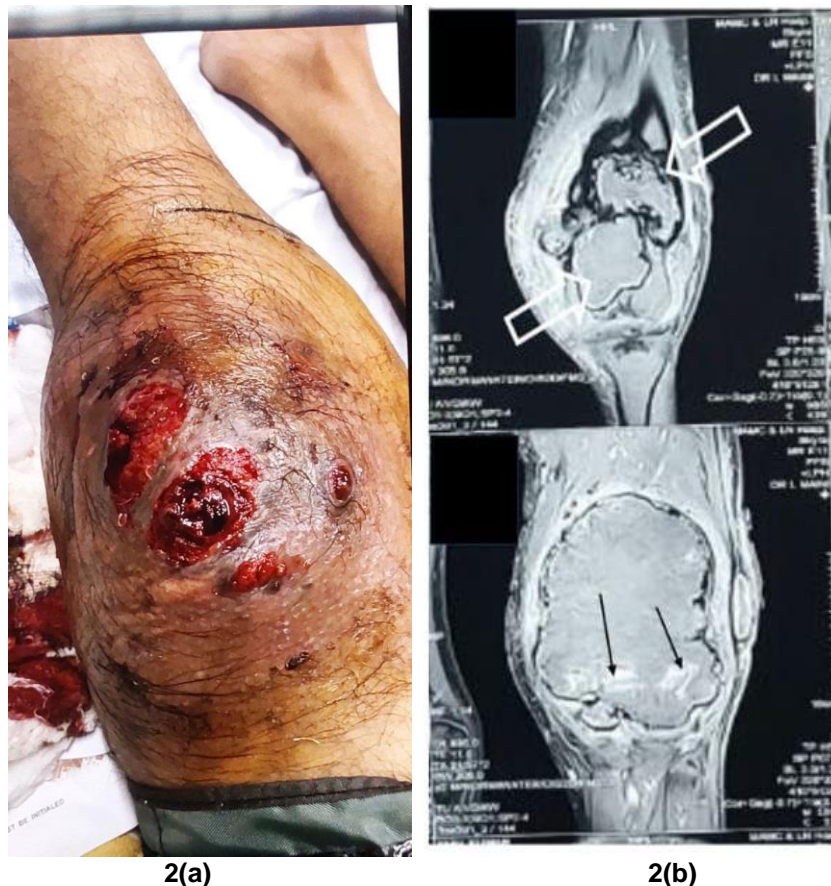be salvaged. Postoperative AHF transfusions were administered for 7 days, with no re-bleeding episodes during follow-up (Srivastava et al., 2020).

On follow-up, the patient was advised for low-dose prophylaxis of AHF to which the patient refused, owing to some personal reasons.

**Case 3:** MRI of the abdomen showed an 8x8x9 cm pseudotumor in the peri-fascial plane, surrounding the psoas muscle in the dorso-lumbar paravertebral region, with no feeding vessels or adjacent necrosis [Fig. 3(a)]. The pseudotumor had a dense, non-enhanced wall, indicating its chronic nature. The patient received AHF one day before undergoing limited local excision. Approximately 300 cm<sup>3</sup> of pseudotumor tissue, blood, and clots were removed, followed by intralesional tranexamic acid injections [Fig. 3(b)]. Postoperative ultrasonography showed a reduced pseudotumor size of 2x2x3

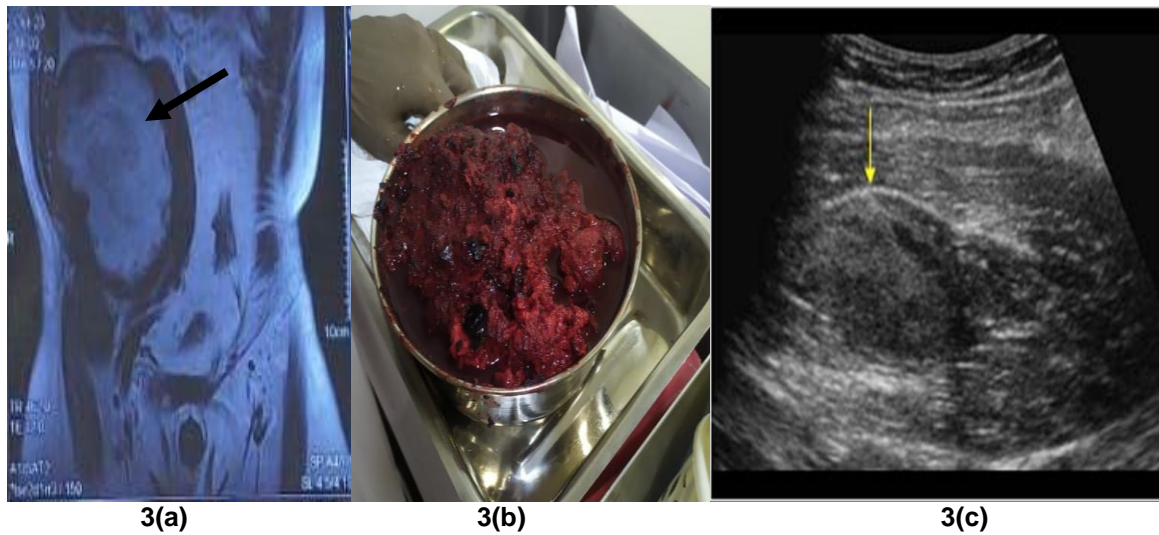
cm [Fig. 3(c)]. The patient was discharged with Vacuum-assisted closure (VAC) dressing and is now on Emicizumab prophylaxis. His functional status is nearly fully restored.

**Case 4:** Due to the alarming symptom of hemoptysis, the patient underwent a chest radiograph and sputum analysis. The sputum results were normal, but the radiograph revealed a loculated mass in the left lung's lower zone [Fig. 4(a)]. A subsequent CECT chest scan identified a 12x11x7 cm pleural-based lump arising from the intercostal muscles. The mass had a thick wall (~9 mm) but no necrosis [Fig. 4(b)]. A diagnosis of left pleural pseudotumor was made. Since the patient was asymptomatic during the hospital stay, a conservative approach of watchful monitoring was chosen. Regular follow-ups and scans will track any changes. The patient is currently on low-dose AHF prophylaxis, with no worsening signs observed.



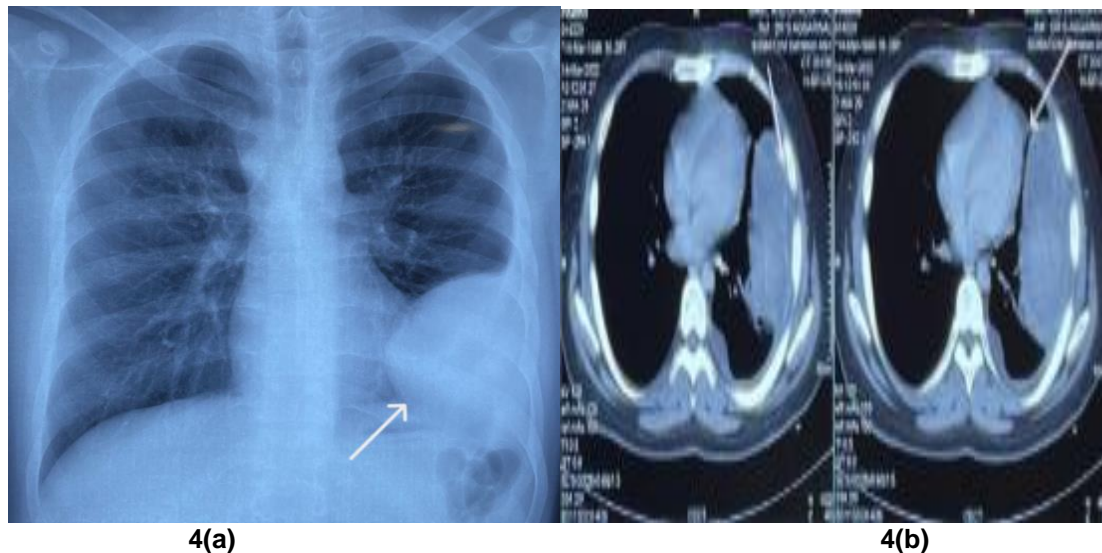
**Fig. 2. Gross and radiological images of the second case**

2(a): The right knee pseudotumor with multiple excoriations with oozing of blood as seen  
2(b): Pre-operative MRI images of right knee joint pseudotumor with areas of cystic consistencies marked by 2 white hollow arrows in the upper image and 2 black solid arrows in the lower image



**Fig. 3. Images of right iliac fossa pseudotumor**

3(a): MRI abdomen of the patient showing the extent of the pseudotumor, lying closely to the psoas muscle, highlighted in a black solid arrow; 3(b): Gross section of the excised pseudotumor tissues showing fibrous wall with compact and clotted blood intermixed within; 3(c): Ultrasonography done in the post-operative period showing the reduced size of the pseudotumor, marked by a yellow solid arrow



**Fig. 4. Chest radiograph and CECT chest of the patient showing the pleural-based pseudotumor**

4(a): Chest radiograph showing a mass in the left sixth intercostal space, arising from the pleural surfaces likely pseudotumor; 4(b): CECT chest showing pleural-based pseudotumor that was likely responsible for the causation of hemoptysis in the patient. No obvious communication with the airways could be seen

#### 4. DISCUSSION

Starker was the first to describe the hemophilic pseudotumor in a 14-year-old boy's femur. Only 1% to 2% of patients with severe illness get a hemophilic pseudotumor. Because factor replacement therapy has improved hemorrhagic episode control, the incidence of pseudotumor may have been reduced (Hermann et

al., 1986). The compressive effect of pseudotumors on nearby structures, such as bone loss, muscle necrosis, and skin necrosis, is the main cause of morbidity due to pseudotumors (Rodriguez-Merchan, 2002). A conservative approach is preferred for pseudotumor caused by recent hemorrhage, which includes factor replacement and immobilization of the affected area. While in the

case of chronic pseudotumor operative management is preferred ( Li, 2013).

Treatment options for hemophilic pseudotumors depend on the tumor's location and duration. A conservative approach, including factor replacement and immobilization, is typically preferred for pseudotumors caused by recent hemorrhages. However, chronic pseudotumors often require surgical intervention (Osooli et al., 2019), (López-Gómez et al., 2014). Intraoperative and postoperative complications may include increased bleeding, difficulty achieving hemostasis, nerve and vessel injury, fistula formation, abscesses, recurrence of the pseudotumor, and even death.

Surgical treatment is advised for hemophilic pseudotumors that continue to enlarge or cause hemodynamic instability or other complications (López-Gómez et al., 2014). The risk of surgical bleeding can be minimized by administering AHF during the surgery, under the close supervision of hematologists. An alternative approach is arterial embolization followed by surgical excision, which helps reduce vascularization and thus decreases the risk of bleeding (Espandar et al., 2009). During surgery, factor levels should be maintained at 100%, tapering to 50% for two weeks postoperatively, to lower the chances of bleeding complications.

Primary hematological prophylaxis has significantly reduced the incidence of pseudotumors, reflecting the quality of a country's care. Low-dose prophylaxis in hemophilia, through regular clotting factor administration, prevents repeated bleeding episodes that contribute to pseudotumor formation. Maintaining baseline clotting levels minimizes the frequency and severity of hemorrhages, particularly in joints and muscles. Early, consistent prophylaxis helps control bleeding, reducing chronic hematoma formation and the likelihood of pseudotumors in hemophilia patients ( Atilla and Güney-Deniz, 2019).

Radiotherapy is a viable alternative when surgery is not feasible and conservative treatments fail. It works by causing radiation-induced damage to blood vessels and fibrosis in the pseudotumor's cellular components. Radiotherapy has been effective in treating recurrent pseudotumors, especially in the long bones (Shinto, 2015).

Perioperative blood loss, pseudotumor recurrence, and infection were also important

matters that the surgeons considered. He et al-retrospectively reviewed 18 pseudotumor patients who underwent surgical treatment (He et al., 2019). Over 40 years in China, of those, 15 patients received resection or resection and reconstruction, and two recurrences were observed. In contrast, Panotopoulos et al analyzed six patients with a hemophilic pseudotumor who were treated through surgical treatment (Panotopoulos et al., 2012). At the latest follow-up after 8.4 (range, 4–24) years, no recurrence was observed. In our case also no recurrence was seen, though our period of follow-up is still ongoing.

Ahuja et al demonstrated a combination of the above-mentioned modalities in their case report (Ahuja et al., 2007). The patient was initially treated with recombinant factor VIII and radiation therapy. Because of inadequate response and worsening of bony erosion, the patient had a preoperative embolization followed by surgical excision. The surgical procedure was associated with minimal blood loss and the patient had a relatively smooth postoperative course with no physical morbidity.

The incidence of hemophilic pseudotumors has significantly decreased due to advances in hemophilia management, including improved factor replacement, early diagnosis, and widespread prophylaxis. Regular clotting factor infusions prevent chronic bleeds, reducing pseudotumor formation. Early detection through advanced imaging (MRI, CT) allows for timely treatment, often through surgery or radiotherapy. Comprehensive care programs and specialized hemophilia centers enhance treatment outcomes. However, in developing countries like India, affordability remains a challenge despite increased treatment availability.

A part of such a comprehensive program is the Hemophilia Day Care Centre, LNH, New Delhi. The centre caters a near total of 6000 hemophiliacs. 220 of those 6000 hemophiliacs are enrolled in a low-dose prophylaxis program. Only 4% receive AHF prophylaxis, due to financial limitations, social barriers, and regional practices, though tremendous efforts are ongoing to expand the program. All the cases who presented with the following complications were diagnosed cases of Hemophilia from the same centre. Proper workup of mixing studies, factor levels, and inhibitor assays was done for them before making their diagnosis of Hemophilia.

Their complications were also addressed along with their diagnostic assessment.

In our case series, we presented 4 diagnosed cases of Hemophilia who presented with different kinds of pseudotumors. All had their specific sets of intricacies and complexities, and all were managed accordingly. It sheds some light on the management of pseudotumors of Hemophilia in a resource-limited setting. Many options for treatment and prophylaxis are available but not all are easily available and affordable in this part of the world. Financial constraints are the biggest drawback that hinders patient management in many parts of the developing world.

## 5. CONCLUSION

Early detection of compressive symptoms is important in hemophilic pseudotumors because it allows for accurate surgical planning and treatment.

To conclude, patients having recent hemorrhage should be managed with a conservative approach while surgery should be the preferred modality in case of chronic cases especially those causing pain and pressure symptoms. The primary aim of this case report is to highlight the requirement for surgical interventions in hemophilia.

The intervention, although rigorous, is required as urgently in a hemophiliac as in a normal patient. Inadequate hemostatic control could be a major cause of morbidity and mortality. Hence, the decision to perform surgery should be made carefully, keeping in mind the need for a multi-specialty approach.

## DISCLAIMER (ARTIFICIAL INTELLIGENCE)

Author(s) hereby declare that NO generative AI technologies such as Large Language Models (ChatGPT, COPILOT, etc) and text-to-image generators have been used during writing or editing of this manuscript.

## CONSENT

As per international standards or university standards, patient(s) written consent has been collected and preserved by the author(s).

## ETHICAL APPROVAL

It is not applicable.

## ACKNOWLEDGEMENTS

I would, on behalf of the entire team of authors, like to extend my thanks to anyone and everyone who has been a part of this article. Very special thanks to my parents, my consultants, and the staff for their tireless help.

## COMPETING INTERESTS

Authors have declared that no competing interests exist.

## REFERENCES

- Ahuja, S. P., Sidonio, R. Jr., Raj, A. B., et al. (2007). Successful combination therapy of a proximal haemophilic pseudotumor with surgery, radiation, and embolization in a child with mild haemophilia A. *Haemophilia*, 13, 209-212.
- Atilla, B., & Güney-Deniz, H. (2019). Musculoskeletal treatment and rehabilitation in haemophilia. *EFORT Open Reviews*, 4(6), 230-239.
- Espandar, R., Heidari, P., & Rodriguez-Merchan, E. C. (2009). Management of haemophilic pseudotumours with special emphasis on radiotherapy and arterial embolization. *Haemophilia*, 15(2), 448-457.
- He, Y., Zhou, X., Cui, H., et al. (2019). Surgical management of haemophilic pseudotumors: Experience in a developing country. *Journal of Investigative Surgery*, 32, 127-136.
- Hermann, G., Yeh, H. C., & Gilbert, M. S. (1986). Computed tomography and ultrasonography of the hemophilic pseudotumor and their use in surgical planning. *Skeletal Radiology*, 15(2), 123-128.
- Li, H., Sun, J., Zhou, X., Liu, Y., Song, X., & Ma, Q. (2013). Clinical predictors for the phenotypic heterogeneity of severe hemophilia A in China. *Nan Fang Yi Ke Da Xue Xue Bao*, 33(3), 424-427.
- López-Gómez, J., Contreras, J. S., Figueroa-Ruiz, M., et al. (2014). Management of the hemophilic pseudotumor of the abdomen: A rare pathological entity. *International Journal of Surgical Case Reports*, 5, 789-792.
- Osooli, M., Donfield, S. M., Carlsson, K. S., et al. (2019). Joint comorbidities among Swedish carriers of haemophilia: A register-based cohort study over 22 years. *Haemophilia*, 25(5), 845-850.

- Panotopoulos, J., Ay, C., Trieb, K., et al. (2012). Surgical treatment of the haemophilic pseudotumour: A single centre experience. *International Orthopaedics*, 36, 2157-2162.
- Rodriguez-Merchan, E. C. (2002). Hemophilic cysts (pseudotumors). *Haemophilia*, 8, 393-401.
- Rodriguez-Merchan, E. C. (2016). Musculo-skeletal manifestations of hemophilia. *Blood Reviews*, 30(5), 401-409.
- Shinto, A. S., Kamaleshwaran, K. K., Chakraborty, S., et al. (2015). Radiosynovectomy of painful synovitis of knee joints due to rheumatoid arthritis by intra-articular administration of (177)Lu-labeled hydroxyapatite particulates: First human study and initial Indian experience. *World Journal of Nuclear Medicine*, 14, 81-88.
- Srivastava, A., Santagostino, E., Dougall, A., et al. (2020). WFH guidelines for the management of hemophilia (3rd ed.). *Haemophilia*, 26(Suppl 6), 1-158.

**Disclaimer/Publisher's Note:** The statements, opinions and data contained in all publications are solely those of the individual author(s) and contributor(s) and not of the publisher and/or the editor(s). This publisher and/or the editor(s) disclaim responsibility for any injury to people or property resulting from any ideas, methods, instructions or products referred to in the content.

© Copyright (2024): Author(s). The licensee is the journal publisher. This is an Open Access article distributed under the terms of the Creative Commons Attribution License (<http://creativecommons.org/licenses/by/4.0>), which permits unrestricted use, distribution, and reproduction in any medium, provided the original work is properly cited.

*Peer-review history:*  
The peer review history for this paper can be accessed here:  
<https://www.sdiarticle5.com/review-history/125109>