

Coverage of Dorsal Tissue Loss of Long Fingers by a Adipofascial Pedunculated Flap

Mohamed Ali Sbai¹, Senda Bellila^{1*} and Ali Gacem¹

¹Department of Plastic, Reconstructive and Burn Surgery, Faculty of Medicine of Tunis, Tahar Maamouri Hospital, Nabeul, El Manar University, Tunisia.

Authors' contributions

This work was carried out in collaboration among all authors. All authors read and approved the final manuscript.

Article Information

Editor(s):

(1) Parth Trivedi, Civil Hospital Campus, India,

Reviewers:

(1) Surendra Pandey, CLS council of Electrohomoeopathy, India.

(2) Fatih Doğan, Adiyaman University, Turkey.

Complete Peer review History: <https://www.sdiarticle4.com/review-history/76714>

Case Study

Received 28 August 2021
Accepted 08 November 2021
Published 13 November 2021

ABSTRACT

Introduction: We report a series of dorsal adipofascial pedunculated cutaneous flaps of fingers used in retrograde or antero-grade flow.

Materials and Methods : This is a retrospective study realized into the plastic surgery department of the Nabeul University Hospital.

Ten flaps were harvested from 10 patients, whose the average age was 40 years, predominantly male (8 men), all losses of substances were post-traumatic, coverage was carried out secondarily in all cases. Four flaps had a retrograde pedicle and 6 antero-grade one. The donor site of the flap was adjacent to the loss of substance in all cases, the loss of residual substance was covered by total skin grafting taken from the anterior face of the wrist.

Results: Temporary distal venous conestion was noted in one case. No necrosis was observed. The quality of tissue coverage did not result in any functional discomfort and was considered satisfactory.

Discussion: These flaps offer a great flexibility of use allowing to adapt as well to its localization and the size of the skin substance loss as to the trophic quality of the skin tissue surrounding it. The homodigital character of these flaps avoids the inconvenience encountered with flaps taken from the back of the hand or cross finger flaps.

*Corresponding author: Email: bellilasenda@gmail.com;

Conclusion: Due to their reliability related to the anastomotic character of their vascularization, these flaps constitute the treatment of choice of the medium-sized losses of distal dorsal tissue of the long fingers, (not exceeding 2,5 cm of long axis).

Keywords: Loss of tissue; long fingers; adipofascial; homodigital flap.

1. INTRODUCTION

The loss of dorsal and distal tissue from long fingers often poses a coverage problem despite the large knowledge of the vascular anatomy of the hand and fingers, the rich vascularization of the hand and the description of new flaps.

The adipofascial pedunculated flap of the long fingers is another attractive solution for covering these losses of substance.

Although it has been described for a long time, it is very little known and little practiced flap.

We present a retrospective study of 10 cases collected in the plastic surgery department of Nabeul hospital, the objective of this work is to recall the surgical anatomy of this flap, show its advantages and disadvantages as well as the indications.

2. MATERIALS AND METHODS

This is a retrospective study of 10 cases of adipofascial pedunculated flaps performed at

Nabeul's plastic surgery department, In patients with loss of dorsal skin substances from long fingers exposing noble elements and requiring flap coverage.

The results were evaluated according to a score taking into account the aesthetic aspect of the coverage and the function of the hand according to the rating of the American Federation of Hand Surgery.

3. RESULTS

Our series consists of ten cases divided into 6 men and 4 women, we found as a medical history 2 cases of diabetes and 1 case of hypertension. Six patients are manual workers. One child is counted within this population. The trauma occurred following a work accident in 8 cases, the crushing mechanism was noted in 6 cases. The dominant side is affected in 6 cases. The average age being 40 years, with extremes of 12 to 65 years, with masculine predominance (8 men).

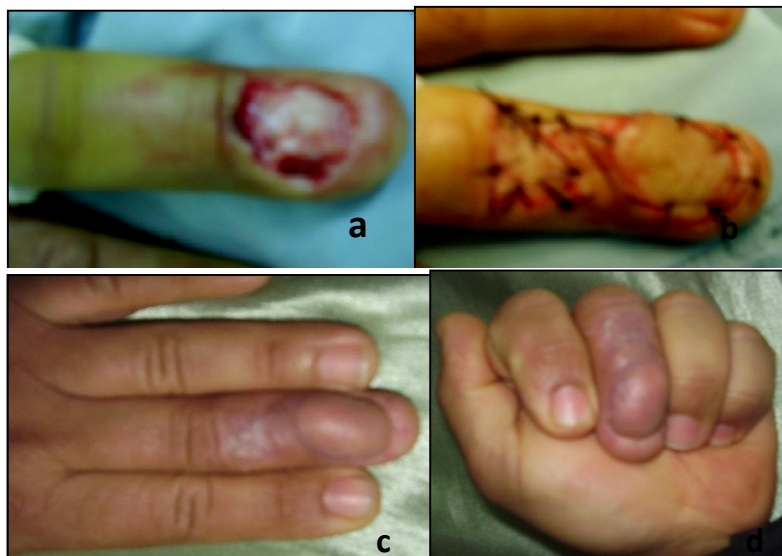


Fig. 1. a. dorsal loss of tissue of the third phalanx b. coverage by an adipofascial pedunculated flap harvested from dorsal tissue of second phalanx c,d. excellent functional outcome

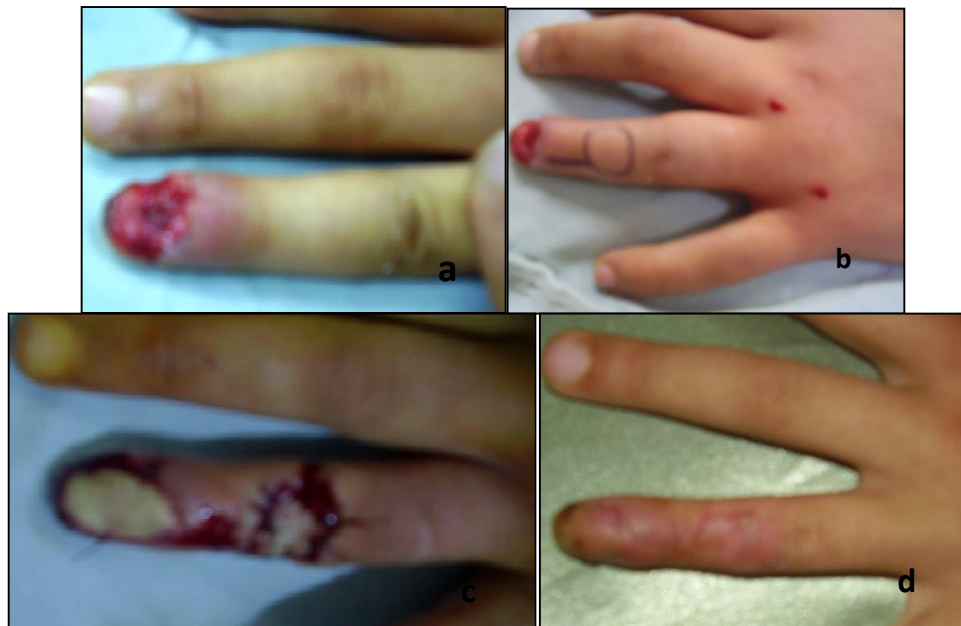

Fig. 2. a. loss of dorsal tissue of the third phalanx b. preoperative design of the flap c. coverage by an adipofascial pedunculated flap harvested from the dorsal tissue of the second phalanx, donor site grafted at the same time d. aspect of the finger after 2 months

The loss of substance being dorsal in all cases, in relation to the first phalanx in 3 patients, to the second phalanx in 4 patients, to the proximal inter-phalangeal joint in one patient and to the third phalanx in two patients.

The trauma affected the index in 2 cases, the middle finger in 3 cases, the ring finger in 2 cases and the pinky finger in 3 cases.

The average size of the loss of tissue is 2 cm², exposing the extensor system in 7 cases, the bone in 2 cases and the proximal interphalangeal joint in one case.

The flap was removed from the dorsal surface of the third phalanx in 4 cases and from the dorsal surface of the second phalanx in 6 cases.

The donor area of the flap was covered by grafting of total skin taken from the anterior face of the wrist at the same surgery in all cases.

Wound healing was obtained after 3 weeks.

We had 3 complications.

A superficial infection of the flap in one case, dyschromic appearance of the donor area grafted in 1 case and a superficial distal suffering

in relation to a venous stasis which evolved favorably.

We didn't note any flap necrosis and has been considered good in all cases.

4. DISCUSSION

The adipofascial pedunculated flap was described by Del Bene in 1994 [1], it consists of a flap taken with a retrograde adipofascial pedicle with retrograde flow. It was then popularized and presented by Bellemere [2] in 2006. Despite its reliability it remains a little known and very little practiced flap, indeed a meta-analysis on the coverage of digital skin tissue loss made by Teemu Karjalainen [3] on 6693 cases, flap was practiced only in 204 cases (3% of cases).

The vascular and surgical anatomy of this flap has been well described. Indeed, the dorsal arterial vascularization of the long fingers is provided by a fine longitudinal anastomotic network located in the adipofascial tissue between the dermis and the extensor system. This network is fed by well-systematized sagittal dorsal branches from the own volar (collateral) digital arteries [4,5,6]. Beyond the proximal third of the proximal phalanx, the anatomical

arrangement of this vascular network presents a constant and identical distribution for all long fingers, and symmetrical between the radial side and the ulnar side of the finger [1]. This network consists of four larger arterioles, located at the level of the distal interphalangeal, in the middle of the middle phalanx, and in the middle and distal third of the proximal phalanx [5,1,7]. The maximum spacing between two sagittal arterioles is approximately 12 mm on either side of the proximal interphalangeal joint. Homodigital dorsal cutaneous flaps can thus be collected in a pedunculated or island manner, based on one of these very short sagittal branches, as proposed by Bertelli [6]. But the richness of the anastomotic network, in the fascial adipo tissue located laterally and at the back of the finger, allows in fact the harvesting of flaps with longer pedicle, adipofascial, with a great flexibility of use. These may be retrograde adipofascial pedunculated flaps randomly collected, as shown by Del Bene [1], anterograde or retrograde flow flaps where the adipo-fascial pedicle is centred on at least one primary arteriole, as proposed by Bellemere [2], or even pure adipo-fascial subcutaneous flaps [8].

The complications of this flap are rare in particular the venous congestion reported by some authors and the necrosis which remains exceptional, it would be more prudent to lift in block the adipofascial tissue, visualize a primary arteriole by transparency and then incise the pedicle by centering it at its base on the selected arteriole. This makes it possible to adapt the length of the pedicle for the needs of flap migration. However, the reduction of the pedicle around this arteriole must not be less than 5 mm. It is necessary to maintain a fascio-adiposal atmosphere including a venous network communicating the dorsal and palmar venous networks to ensure the venous drainage of the flap [9]. This flap was used also in cross finger fashion for adjacent tissue loss [10].

The use of an adipofascial digital flap takes into account several criteria [2,11]:

- The etiology of the loss of substance : it is necessary to avoid the loss of substance by crushing mechanism and excisions following infections because of the risk of vascular damage that can cause necrosis of the flap.
- The localization of loss of substance : When it is on the first two thirds of P1, an anterograde flow flap (taken downstream of the loss of tissue), is required. This avoids

the scar ransom of removing a commissural flap or flaps from the back of the hand. Beyond the proximal two thirds of P1 a retrograde flow flap or anterograde can be used indifferently.

- The size of the substance loss : The maximum size of the flap is determined by the size of a functional unit, that is to say the complete dorsal face to the junction to the palmar tissue of a phalanx or joint, which is about 2,5 x 2,5 cm. Beyond this surface, the aesthetic and functional damage associated with the removal of a homodigital flap seems too important to us.
- the extent of associated skin lesions : It may be a wound, contusion, or scars on the periphery of the loss of substance and requiring harvesting a remote flap with a pedicle located outside these lesions. The maximum migration of a remotely collected flap is represented by an interval of functional unit (back of P1 to back of P2 or back of proximal interphalangeal joint to back of distal interphalangeal joint or vice versa). Beyond such an interval, the length of the pedicle could lead to vascular disorders, especially venous, as well as unsightly tissue redundancy.
- The laterality or not of the loss of substance : A loss of lateralized tissue, even if extensive, may authorize harvesting of a flap with part of the pedicle included in the subcutaneous tissue at the periphery of the loss of substance if it is intact.

5. CONCLUSION

The adipofascial pedunculate flap enriches the therapeutic arsenal in terms of coverage of losses of distal dorsal skin substance of long fingers, it is a reliable flap, indicated in losses of small and medium sized dorsal digital substance, easy realization and allows with other coverage processes to free the fingers from cross finger flaps.

CONSENT

As per international standard or university standard, patients' written consent has been collected and preserved by the author(s).

ETHICAL APPROVAL

As per international standard or university standard written ethical approval has been collected and preserved by the author(s).

COMPETING INTERESTS

Authors have declared that no competing interests exist.

REFERENCES

1. Del Bene M, Petrolati M, Raimondi P, Tremolada C, Muset A. Reverse dorsal digital Island Flap. *Plast Reconstr Surg*. 1994;93:552–7.
2. Bellemère P, Poirier P, Gaisne E, Loubersac T, Kerjean Y, Chaise F, Friol JP, Thebaud A. Les lambeaux cutanés à pédicule adipofascial de la face dorsale des doigts longs. *Chirurgie de la main*. 2006;25:63–68.
3. Teemu Karjalainen, MD, PhDa,b, Jarkko Jokihäärä, MD, PhDc,d . A Review and Metaanalysis of Adverse Events Related to Local Flap Reconstruction for Digital Soft Tissue Defects. *Hand Clin* 36. 2020:107–121.
4. Oberlin C, Sarcy JL, Alnot JY. Apport artériel cutané de la main : application à la réalisation des lambeaux en îlot. *Ann Chir Main*. 1988;7:122– 5.
5. Strauch B, De Moura W. Arterial system of the fingers. *J Hand Surg*. 1990;15A: 148–54.
6. Bertelli JA, Pagliei A. Direct and reversed flow proximal phalangeal island flaps. *J Hand Surg* 1994;19A: 671–80.
7. Valenti P, Masquelet AC, Begue T. Anatomic basis of a dorso commissural flap from the 2nd, 3rd and 4th intermetacarpal spaces. *Surg Radiol Anat* 1990;12:235–9.
8. Legaillard P, Grangier Y, Casoli V, Martin D, Baudet J. Le lambeau boomerang: véritable lambeau cross finger pédiculé en un temps. *Ann Chir Plast Esthet* 1996; 41:251–8.
9. Moss SH, Schwartz KS, Von Drasek-Ascher G, Ogden II LL, Wheeler CS, Lister GD. Digital venous anatomy. *J Hand Surg* 1985; 10A:473–82.
10. M M Al-Qattan. The cross-digital dorsal adipofascial flap. 2008;60(2):150-3.
11. Kento Hosomi, MD, Motonao Iwasawa MD, Yoshito Mishima, MD Tatsuya Kawamura, MD,† and Fumio Nagai, MD‡. Gliding Tissue Reconstruction Using a Dorsal Digital Adipofascial Flap in Complex Extensor Injury. *Ann Plast Surg*. 2019;00: 1–5.

© 2021 Sbai et al.; This is an Open Access article distributed under the terms of the Creative Commons Attribution License (<http://creativecommons.org/licenses/by/4.0>), which permits unrestricted use, distribution, and reproduction in any medium, provided the original work is properly cited.

Peer-review history:

The peer review history for this paper can be accessed here:
<https://www.sdiarticle4.com/review-history/76714>